

CASE STUDY

Ayurvedic Management of Juvenile Spondyloarthropathy

Narinder Sharma^{1*}, Suresh Sharma², Amit Mahajan³

¹Consultant, Department of Kaumarbhritya, Government Ayurvedic Medical College Akhnoor, Jammu, Jammu and Kashmir, India.

²Deputy Director, Department of Ayush, Jammu, Jammu and Kashmir, India.

³Medical Officer, Department of Ayush, Jammu, Jammu and Kashmir, India.

ARTICLE INFO

Article history:

Received on: 21-06-2024

Accepted on: 14-07-2024

Published on: 31-07-2024

Key words:

Ankylosing spondylitis,
Herbal drugs,
Psoriatic arthritis,
Spondyloarthropathies

ABSTRACT

Spondyloarthropathies, chronic inflammatory diseases of the spine and peripheral joints, and juvenile spondyloarthropathies are inflammatory arthritis before the age of 16 years and are characterized by the involvement of both synovium and entheses leading to spinal and oligoarticular peripheral arthritis, principally in genetically predisposed (HLA-B27) individuals. In this case study, 14-year-old boy with a chief complaint of inability to stand and walk due to pain and swelling in large joints of the body for the past 1 month with swollen left knee and bilateral hip joints with severe muscle atrophy of thigh, pelvic girdle muscles. He was prescribed at the first visit with *Rasnadi Guggulu*, 250 mg twice a day (alleviates pain, reduces joint stiffness, and lowers joint inflammation). *Lakshadi Guggulu*, *Simhnad Guggulu* 250 mg each and *Dashmoolarista* 15 ml with equal quantity of water twice daily after meals for a period of 1 week. Shankh vati 250 mg and Kamdudha Ras 250 mg twice daily and *Panchkarma*, i.e., *Vishgarbha tail* twice a day followed by *baluka Swedana* (sand poultice) for local application were added in the treatment for the next (02) 2 weeks. At the 3rd and 4th weeks, there was very good symptomatic relief but general weakness still there, so *Ashwagandha preparation (Churna)* was started as 1 g twice a day for another 2 weeks. By the end of course of treatment, there was marked decrease in bilateral knee effusion on inspection with no signs of inflammation in any joints of body. The patient was able to walk freely without pain. The use of Ayurvedic (Herbal) formulations and panchakarma procedures are helpful in reducing pain and swelling in patients of spondyloarthropathy.

1. INTRODUCTION

The diseases collectively referred to as spondyloarthropathies include ankylosing spondylitis, psoriatic arthritides, arthritis accompanying inflammatory bowel diseases, and chronic reactive arthritis. Estimates of the prevalence of juvenile ankylosing spondylitis range from 11 to 86/100000 children and psoriatic arthritis from 10 to 15/100000 children. JAS occurs most frequently in older boys, adolescents, and young adults. Human leukocyte antigen – HLA – B27 is strongly associated with JAS (more than 90%) and is found in increased frequency in person having spondyloarthropathies with inflammation of axial skeleton.^[1] The principal clinical entities are enthesitis-related arthritis, undifferentiated spondyloarthritis, ankylosing spondylitis, reactive arthritis, psoriatic arthritis, and enteropathic arthritis.^[2]

Corresponding Author:

Narinder Sharma, Consultant, Department of Kaumarbhritya, Government Ayurvedic Medical College Akhnoor, Jammu, Jammu and Kashmir, India.
Email: dnarindersharma@gmail.com

2. BACKGROUND

2.1. Case History

A 14-year-old adolescent boy visited Kaumarbhritya (Ayurvedic Pediatric) outpatient department (OPD) along with parents with a chief complaint of inability to stand and walk due to pain and swelling in large joints of the body for the past 1 month. The patient was taking anti-inflammatory and analgesic for the complaints for the last 1 month with minimal relief.

On inquiry, the patient told that the onset was acute with overnight pain and swelling of the left ankle joint, which was followed by swelling and pain in the left knee joint in few days. Then, the pain and swelling gradually involve the right knee joint as well. In between the treatment, the patient was suffering from gastritis and GI upset on the 3rd week of treatment. However, treatment remains continuous with any halt.

On inquiry, the patient told that pain is continuous, aching in nature, aggravated in night and by cold foods and movement of joints, mild

relief with pain killers and associated with swelling and stiffness in joints, restricted movements, loss of appetite and fever, and general debility.

There was no history of any major disease, any kind of skin eruptions, pain in eyes, pain or stiffness of small joints of hands or feet, cervical pain, painful micturition, etc.

2.2. Past History

There is a history of enteric fever 3 years back and no other relevant past history.

The patient's diet and nutritional history do not reveal any kind of stressor, he was on vegetarian diet with occasional intake of junk food. There is no history of tea, tobacco, alcohol, or other addictions.

2.3. Family History

Father had suffered some joint problem.

2.4. Examinations

Patient is carried to the OPD with poor general condition, weight 42 kg, height 165 cm, pulse rate 102/min regular, equal in volume febrile (100° f), BP – 110/60 mmHg, marked pallor, dry-coated tongue, no icterus, no gross lymphadenopathy, no clubbing or cyanosis, and no skin lesions.

2.4.1. Chest

Normal in shape and appearance with symmetrical bilateral expansion, normal lung field resonance, and equal bilateral air entry without any added sounds.

2.4.2. CVS

Apex beat in the left 5th intercostals space medial to midclavicular line, S₁S₂ WNL, no murmurs.

2.4.3. Abdomen

Scaphoid abdomen, soft non-tender without any organ palpable.

2.4.4. CNS

Conscious, oriented to time, person and place, cranial nerves - intact.

2.5. Local Examination

2.5.1. Inspection

Swollen left knee, slightly right knee, and bilateral hip joints with severe muscle atrophy of thigh, pelvic girdle muscles

2.5.2. Palpation

All the affected joints were warm and tender with minimal active as well as passive movements.

2.6. Investigations

2.6.1. Initial investigations

- CRP-+ve, Montoux Test - negative, RA factor - negative.
- CBC shows Hb-12.3 g %, TLC-11000/uL, DLC-P-53%, L-34%, E-1 %, M-12%. ESR- 140 mm fall in 1 h
- Repeat CBC after 20 days shows ESR -120 mm fall in 1 h.

2.6.2. At the time of Ayurvedic consultation

- CRP-+ve
- ESR-140 mm fall in 1 h
- HLA B27- +ve.

2.6.3. Key points for the diagnosis

- Adolescent boy
- Asymmetric polyarthritis typically involving lower limbs
- Involvement of capsular attachments
- Involvement of the gastrointestinal tract in the form of episodes of bloody diarrhea
- Patient is positive for HLA-B27.

The patient was thoroughly analyzed according to Ayurvedic norms, from which, by applying the method of exclusion, he was diagnosed as having Amavata^[3] and a treatment strategy was formulated. The *vyadhi* (disease) was considered *yapya*^[4] (treatable). The patient's parents were accordingly counseled regarding the nature of the illness and treatment was then begun.

2.7. Treatment

The objective of the treatment is to reduce the inflammation of joints and provide relief of pain, minimize aam (inflammatory mediators) production by the use of deepan pacana anti-inflammatory drugs. Medications prescribed at the first visit were Rasnadi Guggulu, 250 mg twice a day (alleviates pain, reduces joint stiffness, and lowers joint inflammation). Dashmoolarista 15 ml with equal water twice daily after meals for a period of 1 week, along with Lakshadi Guggulu and Simhnad Guggulu 250 mg each twice daily. The patient was put on bland diet and advised complete rest and hot water fomentation given in Tables 1 and 2.

In the next visit or 2nd week, there was no fresh complaint, mild symptomatic relief, and on examination, knee effusion and tenderness were slightly reduced in size with reduction in inflammatory signs. Two more medicines were added to the treatment for next (02) 2 weeks. Shankh vati 250 mg and Kamdudha Ras 250 mg twice daily and Panchkarma, i.e., Vishgarbha tail twice a day followed by baluka Swedana (sand poultice) for local application.

At 3rd and 4th weeks, there was very good symptomatic relief but general weakness still there, so Ashwagandha preparation (Churna) was started as 1 gm twice a day for another 2 weeks. By the end of course of treatment, there was marked decrease in bilateral knee effusion on inspection with no signs of inflammation in any joints of body. The patient was able to walk freely without pain.

The oral medication was continued for the next 3 months to prevent relapse of the disease.

2.8. Diet

Light bland diet was prescribed throughout the treatment and was indicated during follow-up period also.

3. RESULTS

During initial phase of treatment, the patient get through the pain because of the absence of painkillers. As he bit by bit began to improve, and when the fever had subsided, recuperation was quick. After the course of treatment, his hunger improved and he was completely feeling relieved from pain. He was able to move his joints freely without stiffness and do his everyday activities. His ESR, which was at the first 140/1st h, had come down to 18/1st h following 3 months of treatment as shown in Figures 1 and 2. Taking into account, the nature of the disease, despite the fact that the patient was free from complaints, chances of relapse were considerable.

4. DISCUSSION

The first step in initializing Ayurvedic treatment is to arrive at as precise a diagnosis as possible based on its principles.^[4] The condition was approached and managed with the principles of the management of Aamvata. In Aamvata, there are two triggering factors contributing to the pathogenesis of the disease. The production of Aam and also the Vata prakopa. According to Ayurveda, the treatment of Aamvata includes treating Aam with Langhan, Deepana, Pachan with tikta, and Katu dravyas followed by local panchkarma procedures.^[5]

In this case, the first line of drugs includes deepana and pachana with Rasnadi Gugglu^[6] and the use of Vata anulomana and vata shaman drugs such as Dashmoolaristam and Lakshadi Gugglu Simhnad Gugglu. As there was good initial response in the reduction of pain, the same treatment plan was advised for the next 2 weeks with addition of Shankhvati and Kamdudha Ras for increasing agni (metabolism) and local snehana with oil to reduce Vata. But as the swelling persist even after treatment for 3 weeks, addition of a Ashwagandha preparation as rasayana and vata pacifying agent was prescribed for 1 week to reduce swelling but after partial remission, the patient was advised for swedna with Potali initially followed by Baluka swedana for 2 weeks. This completes the treatment regimen of the patient and was completely relieved of pain and swelling of joints. For prevention of the condition, some rasayana, deepana, pachana, and Vata shaman drugs were continued for the next 3 months.

5. CONCLUSION

This case features the way that certainty can be put in Ayurvedic treatment standards even in situations where allopathic medication's prognosis is poor. The patient was analyzed in Ayurvedic terms and treated accordingly. This case study concludes that the use of Ayurvedic (Herbal) formulations and panchkarma procedures are helpful in reducing pain and swelling in patient with spondyloarthritis. Ayurvedic management can induce early remission of the disease and can prevent further relapses. However, clinical trials with large number of patients are required to further validate the results.

6. ACKNOWLEDGMENT

Nil.

7. AUTHORS' CONTRIBUTIONS

All the authors contributed equally in design and execution of the article.

8. FUNDING

Nil.

9. ETHICAL APPROVALS

This manuscript does not require ethical approval as it is a case study.

10. CONFLICTS OF INTEREST

Nil.

11. DATA AVAILABILITY

This is an original manuscript and all data are available for only review purposes from principal investigators.

12. PUBLISHERS NOTE

This journal remains neutral with regard to jurisdictional claims in published institutional affiliation.

REFERENCES

1. Kliegman R, Behraman R, Jonson H, Stanton B. Nelson Textbook of Pediatrics. Vol. 1., Part I., Ch. 155. Philadelphia, PA: Saunders; 2008.
2. Kiratiseavee S. Spondyloarthropathies: Using presentation to make the diagnosis. Cleveland Clin J Med 2004;71:3.
3. Sastri L. Yoga Ratnakara. Varanasi: Chaukhamba Sankrith Samsthan; 2002.
4. Acharya YT. Charaka Samhitha of Agnivesa with Chakrapani Tika. Varanasi: Chaukhamba Sanskrit Samsthan; 2001.
5. Dutta C. Chakradutta, Ratnaprabha- Hindi Commentary by Sadnand Sharma. Aamvata Chikitsa, Verses 1. Delhi: Meharchand Lachhman Das Publications; 2000. p. 185.
6. Ministry of Health and Family Welfare. Database on Medicinal Plants Used in Ayurveda. New Delhi: CCRAS, Department of ISM and H, Ministry of Health and Family Welfare, Govt. of India; 2002.

How to cite this article:

Sharma N, Sharma S, Mahajan A. Ayurvedic Management of Juvenile Spondyloarthritis. IRJAY. [online] 2024;7(7):43-46.

Available from: <https://irjay.com>

DOI link- <https://doi.org/10.48165/IRJAY.2024.70708>

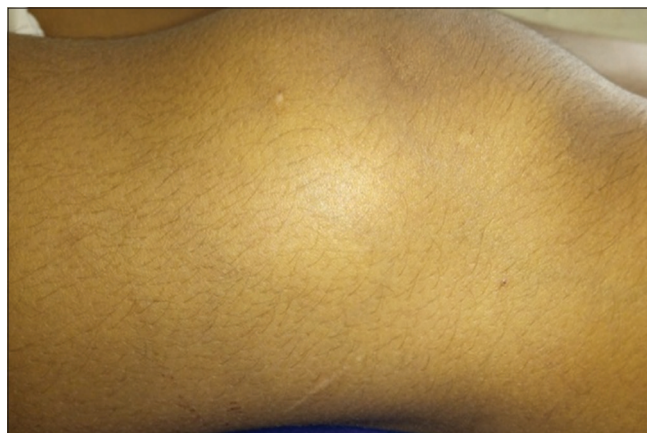

Figure 1: Before treatment

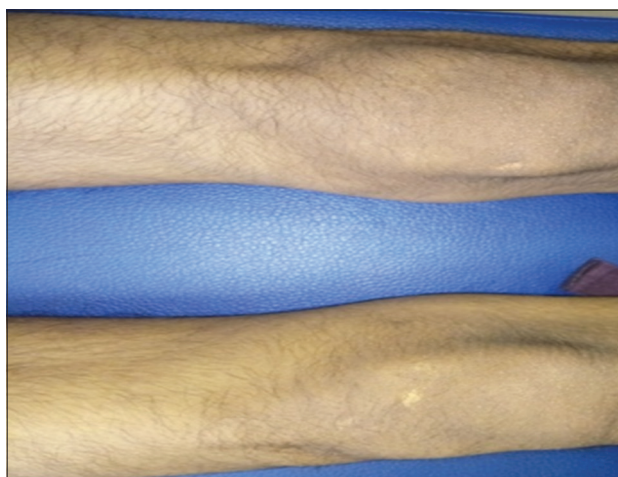


Figure 2: After treatment

Table 1: Ashthavidha Pariksha

1.	<i>Nadi</i>	<i>Vataj</i> , 102/min., regular, equal in volume
2.	<i>Mala</i>	<i>Baddha</i> +
3.	<i>Mutra</i>	<i>Prakrita</i> 4–6/day 1/night
4.	<i>Jivha</i>	<i>Lipta</i> , coated
5.	<i>Shabda</i>	<i>Prakrita</i>
6.	<i>Sparsa</i>	<i>Vikrita</i> – <i>Sarvanga ushnta</i>
7.	<i>Drik</i>	<i>Prakrita</i>
8.	<i>Aakriti</i>	<i>Madhyama</i>

Table 2: Summary of treatment and results

Duration of treatment	Drugs used	Dosage	Rationale of drug use	Results
1 st week	<i>Rasnadi Gugglu</i> <i>Lakshadi Gugglu</i> <i>Simhnad Gugglu</i> <i>Dashmoolarista</i>	250 mg BD 250mg BD 250 mg BD 15 ml BD	<i>Deepana</i> , <i>Pachana Shothahar</i> , <i>Vataghna</i> <i>Shothahar</i> , <i>Vatanuloman</i> <i>Vatanuloman</i>	Reduction in aam signs Reduction in pain Reduction in pain
2 nd –3 rd week	Same as 1 st week+ <i>Shankh Vati</i> <i>Kamdudha Ras</i> <i>Vishgarbha Tail</i> <i>Baluka Swedan</i>	250 mg BD 250 mg BD Local application Local application	<i>Amma pachan</i> , <i>deepan Vatapitta</i> <i>shaman</i> <i>Shothar etc.</i> <i>Vatanuloman</i>	Complete relief in pain and mild reduction in swelling
4 th week	Same as 1 st week+ <i>Ashwagandha Churna</i>	1 g BD	<i>Rasayana</i>	Reduction in swelling and improvement in weakness