



International Research Journal of Ayurveda & Yoga

An International Peer Reviewed Journal for Ayurveda & Yoga



SJIF Impact Factor : 5.69

ISRA Impact Factor : 1.318

ISSN:2581-785X

Case study

Volume: 3

Issue: 9

Successful treatment of *Svabhava satmya Viparyaya Yakrit Kshaya*

(Autoimmune liver cirrhosis) : A case study

Ashok Kumar Panda¹, Ashok Choudhary², Jayram Hazra³

- 1- Research Officer, Central Ayurveda Research Institute of Hepatobiliary Disorders, Bharatpur, Bhubaneswar - 751029, CCRAS, M/O AYUSH, GOI.
- 2- Associate professor of Hepatology and Liver Transplant, Institute of Liver & Biliary science, D-1 Vasant Kunj New Delhi
- 3- Former Director, Central Ayurveda Research Institute of Hepatobiliary Disorders, Bharatpur, Bhubaneswar - 751029, CCRAS, M/O AYUSH, GOI.

ABSTRACT: Presentation of a case of Auto immune liver disease (AILD) which was treated with Ayurveda principles, logic and also tried to established the Ayurveda terminology for the AILD. *Svabhava satmya* is the synergetic properties of *dosas* and *dhatu*s even though the possession of antagonist properties within them and *Svabhava satmya viparyaya* (Auto immunity) is rare condition where synergetic properties of *dosas* and *dhatu*s are lost. It cause many organ specific diseases and *Yakrit Kshaya* (Cirrhosis of liver) is one of them . It is difficult to diagnose without adequate laboratory support. A 57-year women with persistent jaundice, mild ascites, bilateral pedal oedema, with negative viral hepatitis and other metabolic screening is presented. Portal hypertension with Cirrhosis of liver are found in her ultrasound findings before treatment. An extensive interview was conducted with the patient to know the dosh, Prakriti, etc. Herein, a timeline of her diagnosis and treatment are discussed. The patient was prescribed with *Agnideepak*, *srotasodhaka*, *snigdha*, *Mutrala* and *Rasayana* medication and strict diet to treat *Svabhava satmya Virpariyaya Yakrit Kshaya* (Autoimmune liver cirrhosis. *Vardhamana Pippali Rasayana* is not helpful to this case. But current medication is well tolerated and the midline stiff of liver in fibroscan reduced to 27 Kpa from 57 Kpa. Her Portal hypertension is corrected and Liver parenchyma regenerated. The patient has maintained the normal liver enzymes and her overall health is improved even if the drug regimen was stopped after one year. Her therapeutic regimen was tried conservatively as it was successful, so it may be serving a useful therapeutic model for this type of rare Chronic Liver disease (CLD).

Key words- Autoimmune liver diseases, *Rasayana*, *Svabhava satmya Virpariyaya*, *Yakrit Kshaya*

Article received on-11 August 2020

Article send to reviewer on-17 August 2020

Article send back to author on- 9 Sept.2020

Article again received after correction on -21 Sept.2020

Corresponding Author : Ashok Kumar Panda

,Research Officer, Central Ayurveda Research Institute of Hepatobiliary Disorders, Bharatpur, Bhubaneswar -CCRAS, M/O AYUSH, GOI Email id-akpanda_06@yahoo.co.in,

How to Cite the Article : Ashok Kumar Panda, Ashok Choudhary, Jayram Hazra, Successful treatment of *Svabhava satmya Virpariyaya Yakrit Kshaya* (Autoimmune liver cirrhosis) : A case study, IRJAY, September: 2020 Vol- 3. Issue-9: 106-120: Doi: <https://doi.org/10.47223/IRJAY.2020.3913>

INTRODUCTION:

Satmya (Adaptability to health choice and inclination to *Prakruti* (Constitution) compatible food, behavior and life style) is a prime factor in Ayurveda philosophy which maintenance the health and *Asatmya*(non-adaptability) causes diseases. Therefore Ayurveda doctor examines the *Satmya* of every patient in its *Dasavidha parikkhya*(tenfold of comprehensive bio-psycho-spiritual clinical review) as *Asatmya endriyaartha sanyoga* is one of *trividha nidana* . The properties of individual *dosha* and *dhatu* are mutually opposite like- *rukshya guna* of *Vata dosa* and *snigdha guna* of *Kapha dosa* are not interact each other in healthy state. *Svabhava satmya* is the synergetic properties of *dosas* and *dhatu*s even though the possession of antagonist properties. The eccentricity of *Svabhava satmya* can be

called as *Svabhava satmya viparyaya* for the causation of diseases¹. It is a new Ayurveda nomenclature, as *Svabhava satmya* may be called as Auto immunity and *Svabhava satmya viparyaya* may be termed as Auto immune disorders². *Yakrit* (Liver) along with *Pliha* (Spleen) is the roots of *Rakta-vaha Srotas*. *Yakrit* is also chief site for *Ranjaka Pitta*. When the *ushna guna* of *pachaka pitta* is get vitiated in stomach then it disturbed the effect of *Ranjaka Pitta* of Liver. When pitta level is high in Liver, it evaporates the *Kapha* (Water content) and damage the architecture of Liver hence degeneration and dryness of Liver stated. Dry atmosphere in *Yakrit* is helpful for further *Vata* vitiation. Vitiated *vata* further damage the liver or *Svabhava satmya viparyaya* of *dosa* in *Yakrit* vitiated *vata* to trigger

Hepatic stellate cells (HSCs) to change the parenchyma of liver leads to fibrosis i.e. *Yakrit kshaya*³ (liver cirrhosis) and the disease may be named as *Svabhava satmya viparyaya Yakrit kshaya* i.e. Auto Immune Liver Disease (AILD). Autoimmune liver disease is a chronic and long-term pathogenesis of worsen condition of untreated/not proper treated of autoimmune hepatitis. Cirrhosis occurs when scar tissue replaces health parenchyma tissues and block normal flow of blood through liver. It is also regarded as primary biliary cirrhosis⁴. The prevalence of the AILD is around 1-2 per 100,000 populations per year⁵. The occurrence of auto immune liver diseases was 1.3% and 8.7% amongst all liver disease patients and Chronic Liver diseases (CLD) respectively. Autoimmune liver cirrhosis is very common in India. High suspicion raised in all cases of CLDs, middle-aged women who do not have problems with alcoholism and who are without viral aetiology and/or patients with known autoimmune diseases. Auto Immune Liver Disease (ALID) arises on the background of collective genetic and environmental risk, leading to chronic and abnormal hepatobiliary immune responses⁶. Certain risk factors are present in this disease like family history of AIH

and history of bacterial or viral infection. It may associate with Grave's disease, thyroiditis, Type-I Diabetics and Rheumatoid arthritis, and SLE etc. The symptoms are enlarged liver, dark yellow urine, abdominal distension, loss of appetite, itching, Nausea, Vomiting, Joint Pain, abdominal discomfort. The diagnosis can be performing liver function test, viral markers and serologic tests for autoimmune hepatitis like- Anti-Smooth muscle antibodies (ASMA), Anti liver kidney mitochondrial antibodies (anti-LKM), antinuclear antibody (ANA) and serum immunoglobulin IgG. Liver biopsy is confirmatory for diagnosis of AILD⁷. Treatment decisions in autoimmune hepatitis are complicated because of its diverse clinical presentations, uncertain natural history, higher proportion with refractory disease and need of multiple immunosuppressive agents^{8,9}. Some studies suggest that patients with cirrhosis have high risk of deep vein thrombosis (DVT) and pulmonary embolism (PE) and 65-80 percent patients got remission however in years. Nearly three fourth patients have more than five-year survival rate¹⁰. Scientific publications putatively summarised that Ayurveda treatment can slow down, stop and sometimes reverse the

Chronic liver parenchymal diseases. The Ayurvedic treatment of *Yakrit Kshaya* (cirrhosis of liver) can be managed by using the classical treatment principles of *Pandu* and *Kamala*. Primary objective of treatment in *Kamala* is to detoxify the entire body from *gara* and *dushi visha* (artificial and endotoxin) and clear the channels then to introduction of *Sneha* (fat) to reduce dryness. The treatment of *Kamala* is Purgation (*virechana*) to expel aggravated pitta from gut after *snehapana*. *Virechana* (purgation) can also remove the blockage (*sroto sadhana*) by eliminating *kapha* from liver. *Kamyas Rasayana* (Organ specific immuno-modulators) like- *Katuki*, *bhringaraja*, *guduchi*, *pippali*, *Ashwagandha*, *Daruharidra*, *Vidanga* can reduce auto immune process by normalising the T Lymphocyte function and cytokines¹¹.

Patient Information- A 57-year Female patient presented aversion towards food, fullness of stomach, yellow eye with mustard oil colour urine for one year as the chief complains. She has also complained about acidity and joint pain since one and half years. She had been diagnosed with Acute on chronic liver failure (ACLF), Portal hypertension (PHT), Ascites and

Spontaneous bacterial peritonitis (SBP). The patient was afebrile, pale, along with soft and distended abdomen and pitting pedal oedema. She had no history of gastro intestinal bleeding, diabetes or hypertension during the examination. Patient had mentioned no history of blood transfusion, surgery or multiple sexual partners. Patient was intolerant to immunosuppressive therapy. Previously patient is treated with low dose of antibiotics, laxatives, vitamins and antioxidants. Before patient took ayurvedic treatment, she was generally admitted once a month for seven to ten days and received conservative treatment from hepatologist. And when the patient was advised for liver transplant then she came to this hospital.

Clinical findings – In 7th January 2017, her serum total bilirubin was 4.00mg/dl with direct was 1.53mg/dl, SGOT was 151 U/L, SGPT was 63 U/L, alkaline phosphate 158u/l, GGT(Gamma-glutamyl transferase) was 94U/L(Normal range 03-60 U/L), serum Na⁺ was-141.8mmol/L(Normal range-135-148 mmol/L). K⁺ was 4.7 mmol/L (Normal range 3.5-5.3mmol/L),

serum urea-21.0mg/dl (normal range 13-45mg/dl), serum creatinine 1.0(normal range 0.6-1.2mg/dl), total protein 5.7 and serum albumin was 3.4 after administrating 2 units of I.V albumin. Her Prothrombin time (PT) was 22.4, INR-1.8, Haemoglobin was 9.7gm/dl, total thrombocyte (PLT) was 0.41 lakhs/cmm, TLC-5500cells/cumm and ESR 1st hr was 80mm. Her hepatitis A,B,C, E was negative, serum ferritin was 166.8ng/ml (Normal 50-200ng/ml), copper in 24 hour urine was 18.65 ug/L (normal <60.0) , alfa feto protein was 67.00 ng/ml(<10 ng/ml is normal), HbA₁C was 6.3%(<6 non diabetic), anti-smooth muscle anti bodies was negative, Liver Kidney microsomal type 1 antibody (LKM₁) was negative and anti-nuclear anti body Hep-2 was 2.6(normal <1.2).(Table-2). On physical examination, she was emaciated (BMI-18.2), diagnosed with jaundice with bilateral pitting pedal oedema. Her blood

pressure was normal but there was tachycardia (pulse was 102 per minute). The remaining examinations like α_1 -antitrypsin, ceruloplasmin, and thyroid-stimulating hormone levels were within normal limit.

An abdominal ultrasound scan showed a reduced sized liver (10.6cm) with mildly accentuated echotexture, both kidneys and spleen were normal in shape, size and outline, and there was mild ascites with portal hypertension. The patient's *Dosha vidha Prikshya* (Tenfold of comprehensive bio-psycho-spiritual clinical review) as *Pitta vata prakruti, pitta vikruti* , *Avara sara, Avara samhana, Avara satmya, Avara Ahara Shakti and Vyayama Shakti, Madyama Vaya and Pramana, and Kosto* (Bowel Habit) was *kruro*(constipated). The patient's *Asta vidha Pariksha* (eight fold examination) as *Vata pitta Nadi, haridra mutra, tila pista mala, ama lipta* (coated) *Jivha, Pitta predominant Shabda, Sparsa and Drika*, sick and pale in *Akruti* (general appearance).

Table No: -1. Time line of observed symptoms with medication

Time line	Clinical presentation	Medication
D0	Registered with C/o-Yellow Sclera, weakness, loss of appetite, burning stomach, pedal oedema, constipation, sleeplessness, mild body ache & poly arthritis.	1 st phase medication with scheduled Diet
D30	Appetite increase, bowel cleared, Weakness reduced and burning stomach reduced but mild joint pain persists	1 st phase medication with <i>Panchagabya grita</i> (10ml OD at morning empty stomach for introduction of more <i>Sneha</i> .
D45	Pt feels better	<i>Pipalli Vardhamana Rasayana</i> . & Stopped all medication
D54	Severe Chest burn & Gastritis, liver enzyme altered	Concomitant Medication
D60	Patient stable with sr. billurubin. Total raised 2.6mg/dl	1 st phase medication without <i>Panchagavya ghrita</i>
D90	Sclera cleared, bowel movement corrected, weakness further reduced, body ache & poly arthritis persist	1 st phase medication, <i>Potala katu rohinyadi kasaya</i> , <i>Punnvadi Kasaya</i> add on
D180	Good appetite, sleep, bowel movement, weight gain, body ache & poly arthritis still persist	2 nd Phase Treatment for six months
D360	Review and overall health improvement	No medication and advised for maintain weight by exercise and diet adherence
D720	Review& overall health improvement	Normal life with salt and sour diet restriction
D1080	Review& overall health improvement	Normal life with salt and sour diet restriction

Table -2. Showing the Various Medications type and its details

Medication type	Medication details
Phase 1 Medication	<p><i>Suta sekhar Rasa</i>-250mg t.d.s before food with luke warm water</p> <p><i>Agnitundi vati</i> -250mg –tds before food,</p> <p><i>Tivruit leham</i> -10mg at night with hot water,</p> <p><i>Br Lokanth Ras</i>-250mg Bid after food</p>
Phase -2 Medication	<p><i>Lokanath Rasa</i>-250mg Bid after food,</p> <p><i>Guduchi</i> 250 mg tab -500mg BID after food,</p> <p><i>Potala katu rohinyadi kasaya</i> -10 ml mixed with <i>Punnvadi Kasaya</i> -10 ml with equal quantity of water twice before food</p>
Concomitant therapy	Modern Laxative, Low dose antibiotics, antacid and proton pump inhibitors etc -as prescribed by hepatologist
Scheduled Diet	Salt restriction, water intake limited to 1000 ml. <i>Lajja</i> with milk advised twice to the patient. Small tiffin in between meal up to six times, Milk 250 ml, egg white -2 halves.

Time line of Treatment

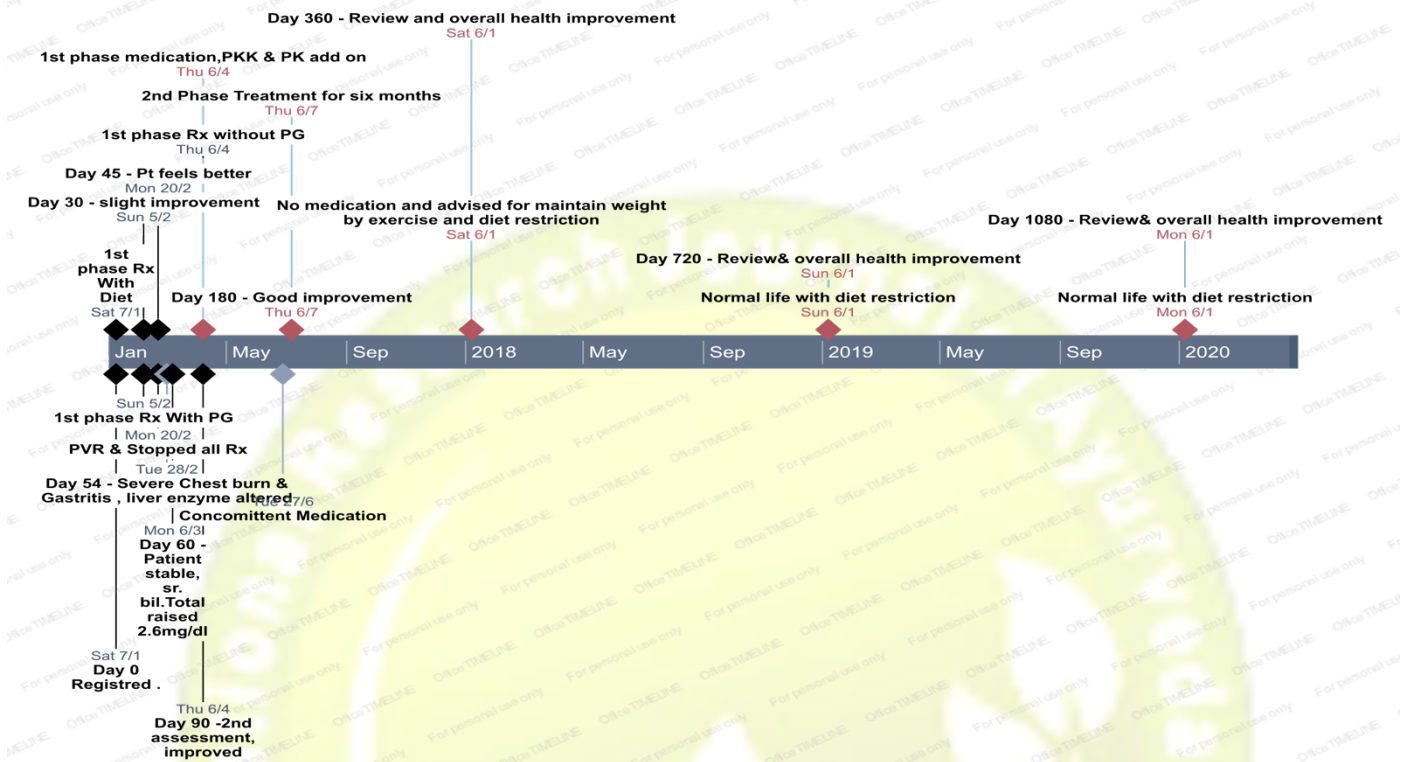


Table 2: Hematological, biochemical and serological parameters during the treatment and observed period.

Lab parameters	At presentation	1month	3months	6months	1year	2year
Hemoglobin(gm/dl)	9.7	11.4	11.9	12.7 gm%	13.6	14.2
ESR 1 st hour	80	60	50	46	50	60
Platelet Count (lakh/mm ³)	0.41	1.1	1.35	1.66	1.95	2.2
TLC (cells/mm ³)	5500	6100	7000	7800	7530	6800
Prothrombin time(second)	22.4	16.0	12.0	15.4	12.4	11.4

INR (Int. normalized ratio)	1.8	1.31	1,66	1.23	1.00	1.00
Sr.Bilirubin(Total)mg/dl	4.0	3.24	1.79	1.2	1.0	0.8
Sr.Bilirubin(Direct) mg/dl	1.53	1.07	0.7	0.5	0.4	0.3
SGOT (IU/L)	151	123	79	60	35	20
SGPT(IU/L)	63	59	57	37	44	20
Alkaline Phosphatase (IU/L)	158	202	136	147	168	118
GGT(U/L)	94	53	50	04	05	03
Total protein (g/dl)	5.7	6.0	6.6	7.0	7.2	7.3
Albumin (g/dl)	3.4	3.1	2.8	3.5	4.3	4.4
Alfa feto protein (ng/ml)	67	-	15	---	05	-
ANA- Hep-2	2.6	-	-	-	0.6	0.2
Urea (mg/dl)	21	14	28	30	17.2	-
Creatinine (mg/dl)	1.0	0.60	0.65	0.66	0.5	-
Na⁺ (mmol/L)	141.8	137	141	136	132	-
K⁺(mmol/L)	4.7	4.5	4.4	4.3	4.1	-
Ultrasound	Cirrhosis & PHT	----		Slight changes	No PHT & cirrhosis	Normal
Liver stiffness (Fibroscan^R)	----	---	57	---	27	14

TLC: Total Leukocyte Count.

SGOT: serum glutamic-oxaloacetic transaminase;

SGPT: serum glutamic-oxaloacetic transaminase.;

GGT: Gamma-glutamyl transferase,

ANA: anti-nuclear anti-body

Na⁺: serum sodium;

K⁺: serum potassium;

PT: prothrombin time;

PHT-Portal Hypertension

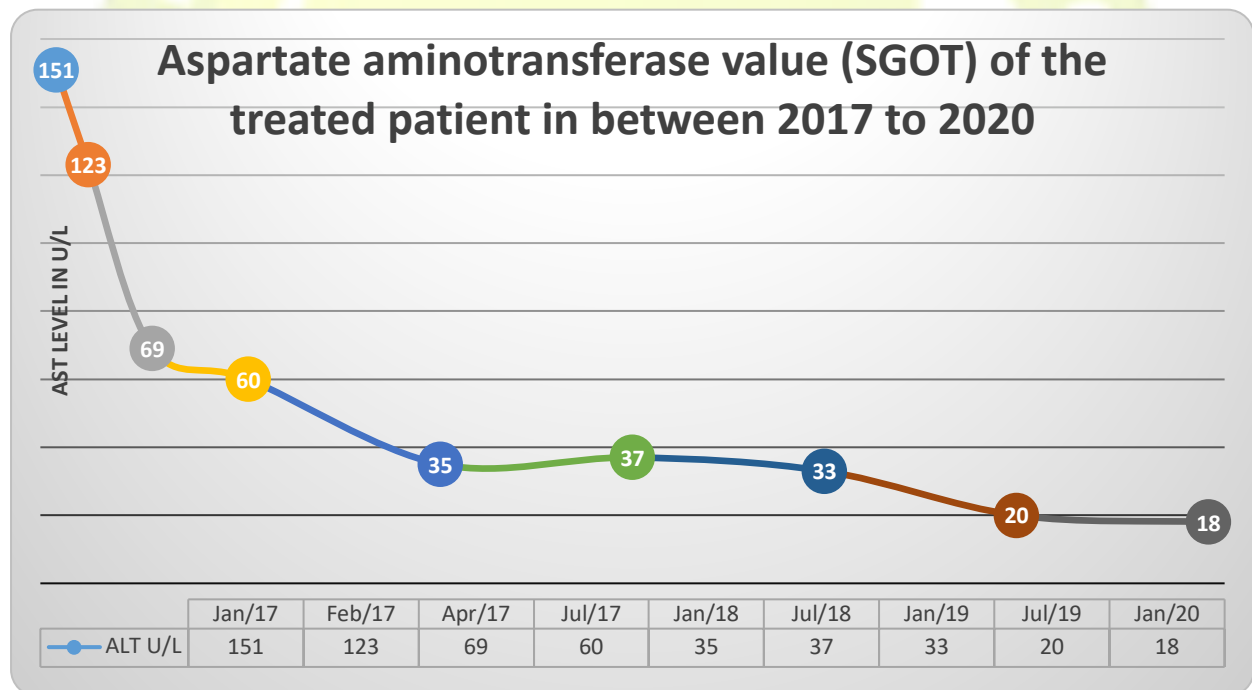


Fig no – 2: Aspartate aminotransferase values for the patient between 2017 to 2020

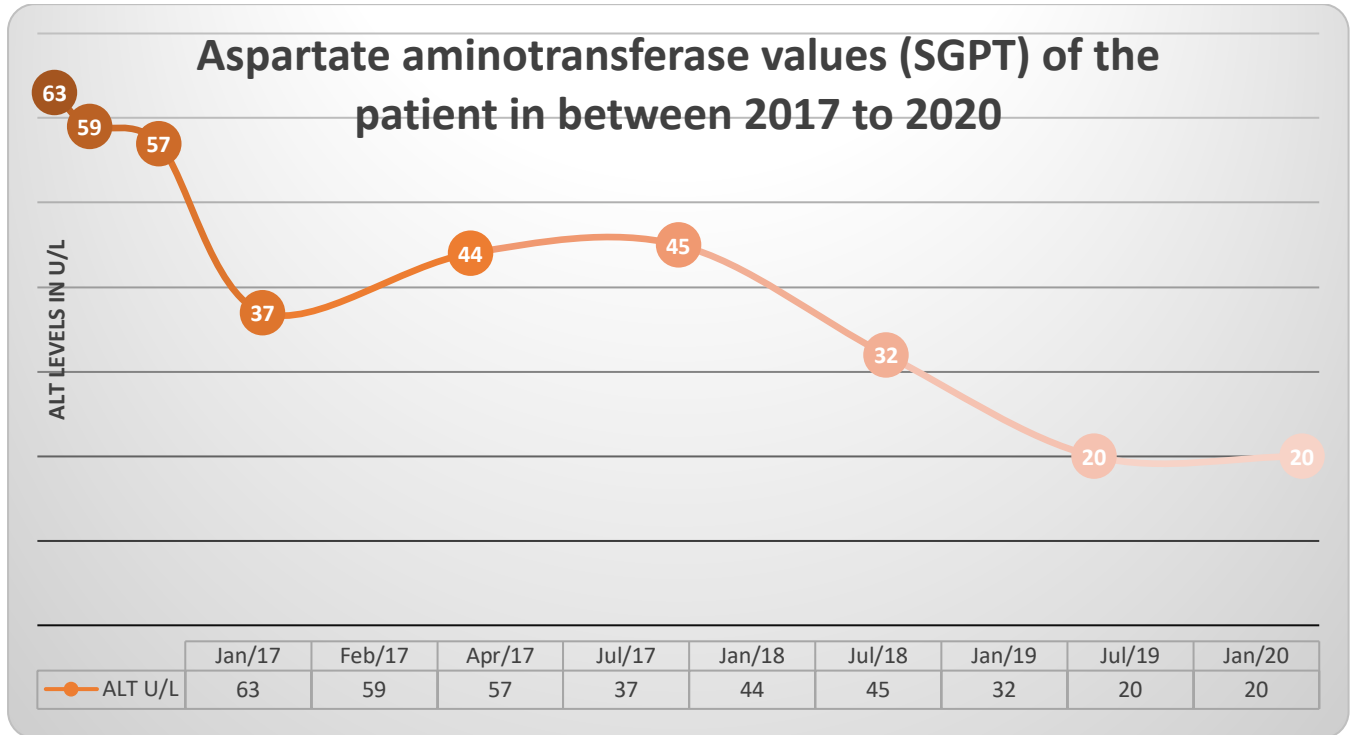


Fig no -3: Alanine aminotransferase (SGPT)levels for the patient between 2017 to 2020

Diagnostic assessment- The diagnosis is based on the extensive interview with patient which revealed that she was not adaptative (*asatmya*) to air condition which they fitted one year back and have irregular food habits along with *viruddha ahara* (wrong combination diet as fish mixed with curd). She has been suffered from gastritis and joint pain before this disease. *Yakrit kshaya* (liver cirrhosis) is conformed from reduced size of liver in ultra sound and increased levels of serum aminotransferases whereas positive ANA

titer and raised ESR leads the diagnosis of liver cirrhosis secondary to autoimmune hepatitis which was made at the end of the evaluation. Haemoglobin, serum albumin, serum transaminase and serum bilirubin along with clinical sign and symptoms are taken as assessment scale for clinical assessment of this patient¹²⁻¹³.

Therapeutic intervention – There is no cure for AILD and no prior evidence of Ayurveda treatment found in extensive internet search. The management of the disease must be individualized. Proper

management of AILD can be alleviate the inflammation of liver tissue, slow the disease development, some cases reverse fibrosis and prolonging the life of the patient, and avoid the need for a liver transplant¹⁴⁻¹⁵. The therapeutic intervention based on the patient interview, as the patient had severe *agni mandya* and gastritis. Therefore, treatment protocol was adopted as *pittasamaka*, *agnideepaka*, *Anulomaka* and *kamalahara*. The medication (*Suta sekhar Rasa*-250mg t.d.s before food with luke warm water, *Agnitundi vati* -250mg –tds before food, *Tivruit leham* -10mg at night with hot water, *Br Lokanth Ras*-250mg Bid after food are prescribed in 1st phase along with prescribed allopathic medication. Sodium restriction was planned in diet along with water intake limited to 1000 ml. *Lajja* and milk advised twice to the patient. On 31st day, *tikshna sneha* and *mamsa rasa* was administered for 15days to rejuvenate liver. On 46th day, *Vardhamana Pippali Rasayana* was planned for better outcome as it has evidence¹⁶. But the treatment of *Vardhamana Pippali Rasayana* intervention was dropped on eighth day of i.e on 54th day, as the patient developed severe chest burning and gastritis. The patient was received concomitant allopathic

medication for six days to reduce severe gastritis Further reported on 60th day, the patient was advised all the 1st Phase medication, except *Panchagavya Ghrita* for another 30days. After completion of 90days treatment low dose *Potala katu rohinyadi kasaya* and *punnavadi kasaya* were given as add on therapy with 1st phase medication for a period of three months. The modern medicines were stopped. (Table no-1& fig no 1)

Further based on the clinical and biochemical improvement the 2nd phase medication (*Lokanath Rasa*-250mg Bid after food, *Guduchi* 250 mg tab -500mg BID after food, *Potala katu rohinyadi kasaya* -10 ml mixed with *Punnvadi Kasaya* -10 ml with equal quantity of water twice before food along with diet as advised) was planned for further six months. *Guduchi* Tablet 500mg bid was administrated as organ specific *Rasayana* to achieve immune modulation¹⁷. Then all medication was stopped and told the patient to review in every six months (Fig :2 & 3).

Follow up and outcome- The patient was followed up in 7 days, 14 days, 30days and 90days, six month and one year. Every six months in consecutive years of follow up. The patients have improved clinically and her hematological, biochemical and serological parameters gradually developed

during the period of time (Table-2). The prescribed medication well tolerated as we were not observed adverse clinical sign and symptoms. The outcome was measured in terms of ultrasound and Fibro scan which showed improved and portal hypertension cleared in one year of treatment. The midline stiff of liver in fibro scan reduced to 27 Kpa from 57 Kpa. The patient has maintained the normal liver enzymes and her overall health is improved even if the drug regimen was stopped after one year (fig: 1 & 2).

DISCUSSION –

The application of *satmya* (Adaptability to health choice and inclination to *Prakruti* compatible food, behavior and life style) in clinical diagnosis and treatment is undetermined by *Ayurveda* clinicians. The patient was diagnosed as *Svabhava satmya Virpariyaya Yakrit Kshaya* (Autoimmune liver cirrhosis) based on her *asatmya* to cold, irregular food habits along with *viruddha ahara* (wrong combination diet as fish mixed with curd). She has also *avara satmya* (more inclination to unwholesome diet) as she had taken more salt and sour food items. The 1st month regimen was *pittasamaka, agnideepaka, Anulomaka* and *kamala hara. The Vardhamana Pippali*

Acknowledgement -The authors are very grateful to Director General and Deputy Director General, CCRAS, New Delhi for providing encouragement and guidance. The authors are thankful to the patient, who have actively cooperated for all investigation.

Rasayana was not tolerated to the patient as she is *pitta prakruti*. *Potala katu rohinyadi kasaya* and *Lokanth Rasa* was studied earlier for *srota sodhaka* and *Kamala hara* respectively¹⁵. *Punnavadi kasaya* was prescribed as *Mutrala* (mild diuretics) to detoxify the body¹⁸. *Guduchi (Tinospora cordilifolia)* can prevent the fibrous changes and promoted regeneration of parenchyma tissues of liver¹⁹. The drug regimen was well tolerated and hematological, biochemical and serological parameters gradually developed during the period of treatment and follow-up. The patient has been successfully off the drug regimen after one year as the desired outcome was achieved in six months. She is living a healthy life despite her liver disease. Her most recent liver function test results were completely normal, which is unusual with AILD.

CONCLUSION-

Svabhava satmya Virpariyaya Yakrit Kshaya (Auto-immune liver cirrhosis) can be treated successfully in *Ayurveda* multiple and complex drug regimen along with restricted diet schedule according to *Raga bala* (strength of disease) and *Rogi bala* (strength of patient).

Financial Assistant:- Nil

Conflict of interest :- Nil

REFERENCES

1. Prof. Yadunandana Upadhyaya, Madhavakara, Madhavanidhanam with Madhukosha Sanskrit commentary of Shri Vijayarakshitha and Shrikantadutta revised and edited Choukamba Sanskrit Sansthan, Varanasi Volume ; 01, Chapter 25, Shloka 2, Page no 460 with page 520.
2. G. Srinibash Acharya, Aberration in Autoimmunity in Ayurveda, Proceeding of International seminar on Integrated approach to Autoimmune disorders, 4th -6th Aug 2019, Haridwar, pp23.
3. Mishra S, Kaviraj Govind Das Sen. Bhaisajya Ratnavali, , Chaukhamba Surbharati Prakashan, 8th revised edition ,1988, Pilha yakrit roga adhikara: Chapter 78, Verse 131-140. pp610-11.
4. Michael P. Manns, Ansgar W. Lohse, Diego Vergani, Autoimmune hepatitis. Update, Journal of Hepatology, 2015, **62**, 1, S100
5. Jepsen P, Grønbaek L, Vilstrup H. Worldwide Incidence of Autoimmune Liver Disease, Dig Dis. 2015;33 Suppl 2:2-12. doi: 10.1159/000440705.
6. Amarapurkar DN¹, Patel ND. Spectrum of autoimmune liver diseases in western India, J Gastroenterol Hepatol. 2007 Dec;22(12):2112-7.
7. Luth S, Herkel J, Kanzler S, Frenzel C, Galle PR, Dienes HP, et al. Serologic markers compared with liver biopsy for monitoring disease activity in autoimmune hepatitis. J Clin Gastroenterol 2008; 42: 926-930.
8. Zachou, P. Muratori, G. K. Koukoulis, A. Granito, N. Gatselis, A. Fabbri, G. N. Dalekos, L. Muratori. Review article: autoimmune hepatitis - current Management and challenges. Alimentary Pharmacology & Therapeutics, 2013, 38, 8, 887
9. Czaja AJ. Difficult treatment decisions in autoimmune hepatitis. WorldJournal of Gastroenterology : WJG. 2010;16(8):934-947. doi:10.3748/wjg.v16.i8.934
10. P Ambrosino, L Tarantino, G Di Minno. The risk of venous thromboembolism in patients with cirrhosis; - Thromb Haemost 2017; 117(01): 139-148, DOI: 10.1160/TH16-06-0450
11. Ashok Kumar Panda & K.K.Rath. Ayurvedic treatment outcome in chronic liver diseases.J Ayurveda Integr Med Sci 2019; 6:190-193.

12. Jemilohun AC, Adewoye OG. LIVER CIRRHOSIS FROM AUTOIMMUNE HEPATITIS IN A NIGERIAN WOMAN: A CASE REPORT. *Ann Ib Postgrad Med.* 2017;15(2):133–136.
13. Brissos J, Carrusca C, Correia M, Cabral J. Autoimmune hepatitis: trust in transaminases. *BMJ Case Rep.* 2014;2014:bcr2014203869. Published 2014 Apr 23. doi:10.1136/bcr-2014-203869
14. Krawitt, EL. Autoimmune hepatitis. *New Engl J Med.* 2006;354(1): 54-66.
15. Ashok Kumar Panda & K.K.Raha . Fibro scan evidence of Reversal of Liver fibrosis by Ayurveda Medication: Case series ; *Journal of clinical and experimental hepatology*, volume-8, page-67.
16. Patel MV, Patel KB, Gupta S, Michalsen A, Stapelfeldt E, Kessler CS. A Complex Multiherbal Regimen Based on Ayurveda Medicine for the Management of Hepatic Cirrhosis Complicated by Ascites: Nonrandomized, Uncontrolled, Single Group, Open-Label Observational Clinical Study. *Evid Based Complement Alternat Med.* 2015;2015:613182. doi:10.1155/2015/613182.
17. Abood WN, Fahmi I, Abdulla MA, Ismail S. Immunomodulatory effect of an isolated fraction from *Tinospora crispa* on intracellular expression of INF- γ , IL-6 and IL-8. *BMC Complement Altern Med.* 2014;14:205. Published 2014 Jun 27. doi:10.1186/1472-6882-14-205
18. Singh RP, Shukla KP, Pandey BC, Singh RG, Singh RH. Recent approach in clinical and experimental evaluation of diuretic action of Punarnava with special reference to nephrotic syndrome. *J Res Educ Indian Med.* 1992;11:29–36
19. Bhawana Sharma, Rajesh Dabur, Protective Effects of *Tinospora cordifolia* on Hepatic and Gastrointestinal Toxicity Induced by Chronic and Moderate Alcoholism, *Alcohol and Alcoholism*, Volume 51, Issue 1, 1 January 2016, Pages 1–10,