

CASE REPORT

A Case Report: *Ksharasutra* Ligation Treatment for *Arsha*

Sonu Swami^{1*}, Vishnu Dutt Sharma²

¹PG Scholar, Department of Shalya Tantra, Post Graduate Institute of Ayurved, Dr S. R. Rajasthan Ayurved University, Jodhpur, Rajasthan, India.

²Associate Professor, Department of Shalya Tantra, Post Graduate Institute of Ayurved, Dr S. R. Rajasthan Ayurved University, Jodhpur, Rajasthan, India.

ARTICLE INFO

Article history:

Received on: 03-07-2023

Accepted on: 20-08-2023

Available online: 31-08-2023

Key words:

Arsha,

Ksharasutra,

Ksharasutra ligation,

Piles

ABSTRACT

Ksharasutra treatment is in practice since ancient time as *Sushruta* has mentioned its application in *Nadivrana*, *Arbuda*, and *Arsha* in *Sushruta Samhita*. It is safe, effective, and economical for the treatment of piles with the least side effect. In this study, a patient was suffering from 3rdo interno-external pile masses at 3, 7, and 11 o'clock with one secondary pile mass at 5 o'clock position of anal canal. All pile masses were treated with *Ksharasutra* ligation (KSL) under spinal anesthesia. Post-operative assessment was done daily by recording the relief observed in signs and symptoms. The ligated pile masses were cut through by 6th/7th post-operative day and resultant wounds were healed latest by 25 days uneventfully. There were some advantages observed in KSL.

1. INTRODUCTION

Varicose veins that are dilated, twisted, and present in the wall of the rectum and anus are known as hemorrhoids or piles. Perverse lifestyle choices, inconsistent and incorrect eating patterns, prolonged sitting or standing, and other factors are among the many factors that contribute to most anorectal disorders by harming the digestive, metabolic, and bowel functions. The most common cause of anorectal issues, which can lead to constipation, is a disturbance of *Jatharagni*. Pile formation results from increased back pressure into the hemorrhoidal veins caused by constipation. A 24-year-old male patient presented with complaints of some mass coming out during defecation and bleeding while passing stool to the *Shalya tantra* outpatient department, Postgraduate Institute of Ayurveda, deemed to be Dr Sarvepalli Radhakrishnan Rajasthan Ayurvedic University, Jodhpur, Rajasthan. The patient was treated successfully with *Kshara Sutra* Transfixion and ligation. The patient's disease is quite embarrassing. The severity of this condition can be understood from the explanations of the Ayurvedic seers *Susruta* and *Vagbhata*, who identified *Arsha* as one of the top eight most untreatable ailments (*Ashta mahagada*) and the most common anorectal disease.^[1] *Arsha* necessitates a surgical procedure in contemporary treatment, such as a hemorrhoidectomy

and rubber band ligation; however, there is a high likelihood that the condition may resurface after some time. The four types of care for *Arsha* have been recommended in Ayurveda, namely *Bheshaj*, *Kshar karma*, *Agnikarma*, and *Shashtra karma*^[2] depending on the disease's presentation and degree of chronicity. *Bheshaj chikitsa* and *Kshar Karma* stand out among them for their remarkable results when used in the direction of *Arsha*. *Kshara* is a caustic chemical with an alkaline pH that is made from the ashes of medicinal plants. Since *Kshara sutra karma* performs the duties of *Chedana*, *Bhedana*, and *Lekhana karmas* without the aid of Shastras, it can take the position of *Shashtra karma*.^[3] As an adjunct to medical procedures, *Kshara sutra karma* can be effectively used by people who are terrified of surgery. That *Ksharasutra* was prepared as per Ayurved Pharmacopeia of India (API) using *Snuhi* (Latex of *Euphorbia nerifolia*), *Apamarga Kshara* (Ash of *Achyranthus aspera* Linn.), and turmeric (*Curcuma longa* Linn.) powder coated over the Barbour's surgical thread No. 20.^[4]

2. CASE REPORT

A 24-year-old male presented to us with complaints of a mass has been coming out during defecation with periodic bleeding per rectum in syringing form and pain in the perianal region for the past 2 months. The patient had a history of constipation for the past 3–4 months. Following detailed history and per rectal examination, the case was diagnosed as "*Abhayantra arsha*" – 3rdo internal hemorrhoids at primary position. The patient was a farmer by occupation.

Corresponding Author:

Sonu Swami,

PG Scholar, Department of Shalya Tantra, Post Graduate Institute of Ayurved, Dr. S. R. Rajasthan Ayurved University, Jodhpur, Rajasthan, India.

Email: sonuswamithegreat@gmail.com

Past History-There was no prior surgical intervention in the patient's history.

2.1. General Examinations

2.1.1. DRE findings

- Perianal region-NAD
- Sphincter tone-normal
- Proctoscopy Examination-3rd internal hemorrhoids at 3, 7, and 11 o'clock position
- Investigations done
- Complete blood count, erythrocyte sedimentation rate, BT, computed tomography, renal function test, random blood sugar, HIV, and HbsAg-within normal limits.

3. MATERIALS AND METHODS

All sorts of references have been collected from our ancient ayurvedic texts, namely, *Sushruta samhita*, *Charaka samhita*, *Dalhana teeka*, *Ashtanga hridaya*, and *Ashtanga samgraha*. Modern books such as Baily and Loves's, Short Practice of Surgery, Surgery of the Anus Rectum and Colon, and Atlas of General Surgery Jaypee Brothers medical publishers are used as literary source.

3.1. Method of *Kshara Sutra* Ligation

3.1.1. Pre-operative

The informed written consent was taken from patient. Shaving and cleaning of peri-anal area was done on 1 day before operation. Sodium phosphates enema on the day of operation was given. Inj. Tetanus Toxoid, 0.5 mL IM was given as prophylactic measure and sensitivity test was done with Inj. Xylocaine on 1 day before operation. The patient was advised to nil by mouth 5 h before surgery. Figure 1 prolapsed pile mass before treatment.

3.1.2. Operative procedure

Patient was laid in lithotomy position after giving local anesthesia. Anus and peri-anal area was painted with betadine solution and spirit. Draping was done with sterilized linen cut sheet. Up to four fingers, anal dilatation was carried out. First of all the interno-external pile mass at 3 o'clock was hold by pile holding forceps. Then, transfixation and ligation were done at the base of pedicle by *Ksharasutra* with help of a round body curved needle. The thread, then, placed along the incised part of interno-external piles mass and reef knot was applied. Same procedure was adopted for piles situated at 7 and 11 o'clock positions of anal canal [Figure 2]. After achieving proper hemostasis, the part was cleaned by betadine solution and betadine ointment was applied. Finally, T-bandage was applied and patient was shifted to the recovery room with stable vitals.

3.1.3. Post-operative

Patient was kept nil by mouth for 6 h. From next morning, Eranda *Bhrishtha Haritaki*, 5 g at bedtime for bowel regulation and *Triphala guggulu*, 500 mg, thrice in a day was prescribed and sitz bath with warm water and *Panchavalka kwatha* for 2 times in a day was advised. Dressing was done regularly and *Matrabasti* with 10 mL *Jatyadi taila* was given daily after dressing. From next day evening, patient advised to take diet such as green vegetables, fruits, rice, *daal*, and plenty of water. Patient was also advised to avoid non-veg, oily as well as spicy foods, junk foods, and alcohol. By 7th post-operative day, some ligated necrosed piles masses were sloughed out and some were required twisting of *Ksharasutra* so that necrosed piles masses were sloughed out and fresh wounds were observed in the respective places

of the pile masses [Figure 3]. Dressing and *Matra Basti* with *Jatyadi taila* was continued for further 10 days. After 10th post-operative day, anal dilatation was started with anal dilator no. 4 lubricated with *Jatyadi ghrita* daily. By the end of 25th post-operative day, all the wounds were observed healed and there was no feature of anal spasm/stricture or any complication [Figure 4].

4. RESULTS

Within 8 days, the patient's pile mass and per rectal hemorrhage had disappeared, and within 18–20 days, all symptoms were vanished. At 25th day, there was no pile mass observed in proctoscopy. Only post-operative scar was seen.

5. DISCUSSION

Sushruta described four therapeutic options for *arsha* (piles), including the use of an *ushadhi* (medicines), *kshara* (external application of cauterization), *agni* (thermal cauterization), and *shastra* (surgery).^[2] The four types of care for *Arsha* have been recommended in Ayurveda, namely *Bheshaj*, *Kshara karma*, *Agnikarma*, and *Shastra karma*, depending on the disease's presentation and degree of chronicity. Two incredibly popular treatments for hemorrhoids, known as *Kshara sutra* therapy and *Kshara karma*, were developed on the solid foundation of the Ayurvedic Samhitas. For 3rd- and 4tho hemorrhoids and hemorrhoids with external components, *kshara sutra* treatment is typically performed. *Ksharasutra* was used in this investigation which was prepared as per API using *S nuhi* (*Latex of Euphorbia nerifolia*), *Apamarga Kshara* (*Ash of Achyranthus aspera* Linn.), and *turmeric* (*C. longa* Linn.) powder coated over the Barbour's surgical thread No. 20. Under spinal anesthesia, it was removed at the latest on the seventh post-operative day. Following the sloughing off pile masses, the chemical cauterization, anti-microbial, and anti-inflammatory properties of the *Kshara* applied to the thread aid in the healing process.^[5] Because *Ksharasutra* has an alkaline pH of 10.3, it prevents bacterial development at the site of ligation. Cutting and sloughing are thought to occur during the first one to 2 days of application of *Kshara*, *Snuhi*, and mechanical pressure effect of *Ksharasutra* ligation (KSL), followed by healing in the remaining days. The turmeric (*C. longa*) powder found in *Ksharasutra* helps the healing process by reducing the reactivity to excessive caustics.^[6] *Ksharasutra* has demonstrated the combined effects of all three herbal medications. *Apamarga Kshara*, *Snuhi Ksheera* and, *Haridra*, said to be unique drug formulation for cutting of piles pedicle as well as healing of resultant wound. *Kshara sutra's* method of action starts in as soon as it makes contact with tissue. *Kshara* infiltrates the lesion's cells up to the mass destruction's engorged tissue forms or the eradication of the pile masses.^[7] Blood may ooze during the cutting effect, but this is stopped by the *Kshara's* sclerosing effect due to its protein's coagulating property. Therefore, there was no possibility of bleeding when the bulk was cut. Due to the anti infectives in *Kshara's* long-lasting effect, the risk of infection is at its lowest. The mechanical strangulation of the blood vessels and tissue caused by the pressure impact of the *kshara sutra* ligation really results in the local necrosis of the pile mass.^[8]

6. CONCLUSION

This case demonstrated that interno-external piles can be treated with KSL without any adverse effects. There is no adverse effect during the post-operative period, such as anal stenosis/stricture, incontinence, and bowel irregularities. *Kshara sutra* ligation treatment is much more beneficial in comparison with hemorrhoidectomy at maximum point. It can be concluded that *kshara sutra* ligation is a standard surgical

treatment modality in the 2nd, 3rd, and 4th of *arsha* (hemorrhoids), which is a low, cost-effective, and affordable treatment for all classes of people in the society. As it is a single case study, so it requires to study in a greater number of patients for concrete conclusion.

7. ACKNOWLEDGMENTS

None.

8. AUTHORS' CONTRIBUTIONS

All authors give equal contribution while preparing manuscript.

9. FUNDING

Nil.

10. ETHICAL APPROVALS

This study not required ethical clearance as it is review study.

11. CONFLICTS OF INTEREST

Nil.

12. DATA AVAILABILITY

This is an original manuscript and all data are available for only review purposes from principal investigators.

13. PUBLISHERS NOTE

This journal remains neutral with regard to jurisdictional claims in published institutional affiliation.

REFERENCES

1. Acharya YT. Sushruta Samhita with Nibandha Sangraha Commentary of Dalhanacharya. 1st ed. Varanasi: Chaukhambha Surabharati Prakasan; 2017. p. 144.
2. Acharya YT. Sushruta Samhita with Ayurved Tatva Sandipika Commentary Chikitsa Sthana. 13th ed., Ch. 6. Sutra 3. Varanasi: Chowkhambha Sanskrit Sansthan; 2001. p. 35.
3. Murthy KR. Srikantha, Translator. Susruta Samhita of Susruta. Sutrasthana; Ksharapaka Vidhi Adhyaaya. Ch. 11. Verse 3. Varanasi: Chaukhamba Orientalia; 2016. p. 63.
4. Unanimously, Ayurvedic Pharmacopia of India Part- II. 1st ed., Vol. 2., Ch. 51. Ksharasutra (Medicated thread). New Delhi: AYUSH, Govt. of India; 2001. p. 209-13.
5. Londonkar M, Reddy VC, Kumar KA. Potential antibacterial and antifungal activity of *Achyranthes aspera* L. Recent Res Sci Technol 2011;3:53-7.
6. Kohli K, Ali J, Ansari MJ, Raheman Z. Curcumin: A natural anti inflammatory agent. Indian J Pharmacol 2005;37:141-7.
7. Farquharsons M, Moran B. Farquharsons, Text Book of Operative General Gurgery. 9th ed. United States: International Student, CRC Press; 2005. p. 439-41.
8. Sharma SK, Sharma KR, Singh K. Kshara Sutra Therapy in fistula-in-ano and other Ano-rectal Disorders. Rashtriya Ayurved Vidyapeeth (National Academy of Ayurveda). New Delhi: RAV Publication; 1994-95. p. 44-5.

How to cite this article:

Swami S, Sharma VD. A Case Report: *ksharsutra* Ligation Treatment for *Arsha*. IRJAY. [online] 2023;6(8):23-26.

Available from: <https://irjay.com>

DOI link- 10.47223/IRJAY.2023.6804

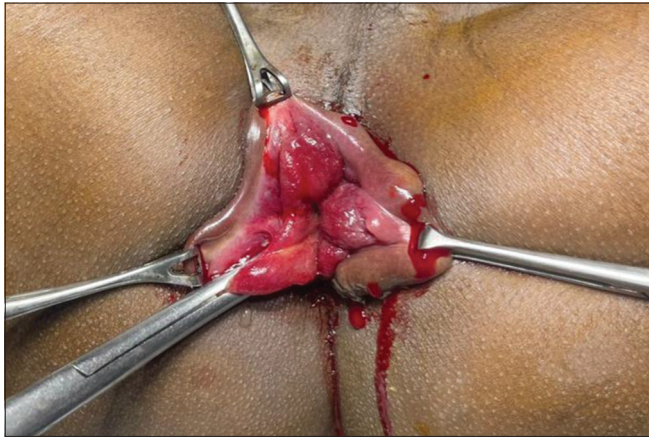

Figure 1: Prolapsed pile mass before treatment

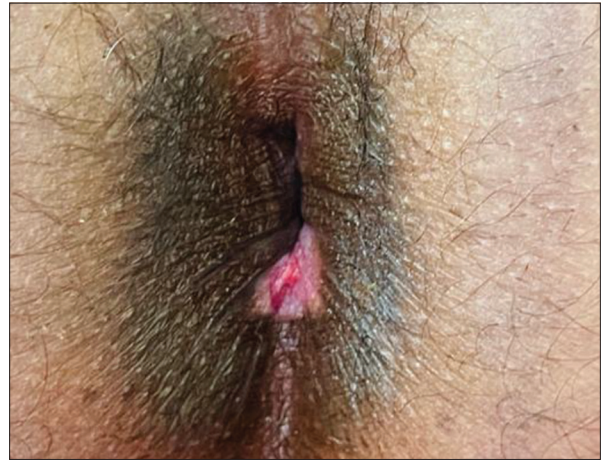

Figure 3: On 7th post-operative day

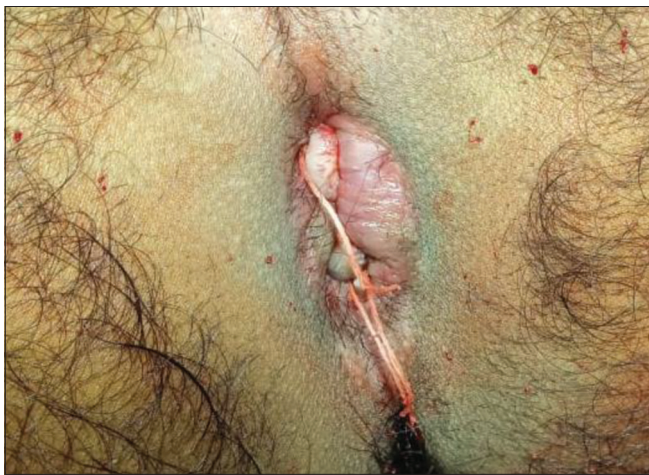

Figure 2: Piles mass after *Kshar* Sutra transfixation and ligation

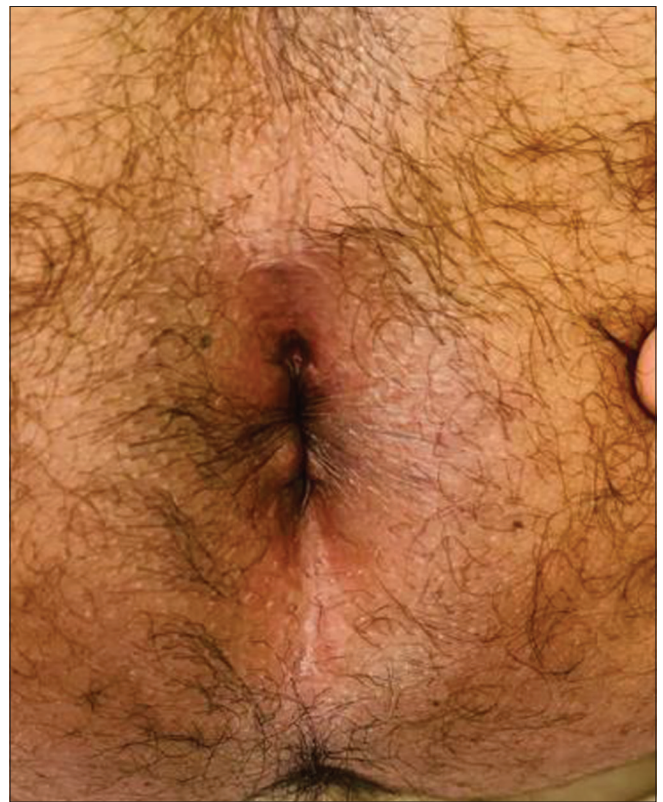


Figure 4: On 25th post-operative day