

## CASE REPORT

# Lipoma of Left Forearm – A Case Report

Jayashree Khuntia<sup>1\*</sup>, Ranjan Kumar Kasta<sup>2</sup>

<sup>1</sup>Scholar, Department of Shalya Tantra, Gopabandhu Ayurveda Mahavidyalaya, Puri, Odisha, India.

<sup>2</sup>Head and Professor, Department of Shalya Tantra, Gopabandhu Ayurveda Mahavidyalaya, Puri, Odisha, India.

### ARTICLE INFO

#### Article history:

Received on: 29-07-2023

Accepted on: 03-10-2023

Available online: 31-10-2023

#### Key words:

Benign form,

Disfigure,

Forearm,

Manual movement,

*Chhedana karma*

### ABSTRACT

Lipomas are the most common benign form among all types of tumors arising from soft tissues. It can occur everywhere on the body, although the majority of cases occur in the head, neck, shoulder, and back region. Those are very uncommon in the hand, especially in the forearm and fingers. Most lipomas are not painful and does not harm to people. However, it disfigures the body part. Hence, the patient wants to remove it. It is a case of 38-year-old woman presented with a lipoma of the forearm. The patient complained of no pain but she felt some difficulty during manual movement. Here, the treatment of choice is *Chhedana karma* (surgical excision of lipoma). As it is atypical, so awareness is imperative since the differential diagnosis from other soft-tissue tumors and from common lipoma classification involved is quite extensive.

## 1. INTRODUCTION

Lipoma is a round or oval-shaped lump of fatty tissue that grows beneath the skin. It moves easily when we touch them and feel rubbery, not hard. It is mainly found in the head-and-neck region as well as shoulder and back region.<sup>[1]</sup> This case is very atypical because it is found especially in the right side left forearm near the left elbow. Lipoma is often called as universal or ubiquitous tumor. It is mainly classified into superficial lipoma (within subcutaneous tissue) and deep lipoma (beneath the fascia).<sup>[2]</sup> Deep lipoma can be further classified into intermuscular, intramuscular, and periosteal. There is another classification of lipoma, i.e., it is divided into 3 types – encapsulated (subcutaneous) variety, diffuse variety, and multiple lipoma. A few lipomas may contain other tissues and are named such as fibrolipoma, naevolipoma, and neurolipoma. Lipoma is commonly found in adults from 40–60 years of age but can be also found in younger adults and children. Superficial or subcutaneous lipoma is a soft, painless nodule consisting of adipocytes most commonly found in back, nape of the neck, and shoulder. It is commonly sessile but occasionally may be pedunculated. Subcutaneous lipoma of the left forearm is rare and benign in this case. Here, the treatment is *chhedana karma* or surgical excision of tumor and resection.<sup>[3]</sup> Resection of lipoma frequently requires incisions equal to diameter of the tumor.

#### Corresponding Author:

Jayashree Khuntia, Scholar, Department of Shalya Tantra, Gopabandhu Ayurveda Mahavidyalaya, Puri, Odisha, India.

Email: [jayashreedr11@gmail.com](mailto:jayashreedr11@gmail.com)

The “Squeeze technique” with a small incision is well described but it is not successful frequently, particularly for lipoma in the shoulder region.<sup>[4,5]</sup> Here, it is a method for subcutaneous lipoma which preserves retaining ligaments.

## 2. CASE PRESENTATION

A 38-year-old female patient complained of painless oval-shaped lump over the left forearm near the left elbow, which is subcutaneous in nature. It is moveable and 2 inches in diameter. It is not fixed to underlying fascia. On clinical examination, she had a soft fluctuant, mobile, elastic mass of left forearm with no disturbance of sensibility. She had no ulceration or pigmentation and no inflammatory changes on the overlying skin. It only disfigured her forearm and some limitation of movement, especially during flexion. Before going for treatment, all the required investigations were done. Then surgery was planned.

### 2.1. Investigation

Before surgery, the required blood tests such as differential count, total leukocyte count, erythrocyte sedimentation rate (ESR), bleeding time, clotting time, hemoglobin %, fasting blood sugar, post-prandial blood sugar, human immunodeficiency virus, and hepatitis B surface antigen are done. ESR is mild high and all other tests are normal. Before surgery, fine needle aspiration cytology (FNAC) suggests that a well-defined oval-shaped homogenous mixed echogenic solid and soft-tissue benign tumor of size 4.8 × 2.5 cm is noted in subcutaneous plain of upper left

forearm with no evidence of intra lesions calcifications or hemorrhage or necrosis. According to FNAC report, it is a subcutaneous lipoma. After surgery, histopathology test is done. It suggests no malignancy. The investigation reports are attached below.

## 2.2. Treatment

The skin was first cleaned with povidone-iodine solution. The incision was configured like a fusiform excision following the skin tension lines and smaller than underlying tumor [Figure 1]. A curette was placed inside the wound and used to free the lipoma from the surrounding tissue. The central island of skin to be excised was grasped with an allis tissue forceps, which was used to provide traction for the removal of tumor [Figure 2]. Dissection was then performed under the subcutaneous fat to the tumor [Figure 3]. Tissue cutting was performed by scissors around the lipoma under direct visualization. Care was taken to avoid injury to nerve or blood vessels which lie just beneath the tumor. Once a portion of lipoma dissected from surrounding tissue, then hemostats are attached with the tumor to provide traction from the remainder of growth. After being free from side, the lipoma was delivered as a whole [Figure 4]. The surrounding tissue was palpated to ensure complete removal of tumor. Adequate hemostasis was achieved following the removal of lipoma. The dead space beneath the skin was closed using interrupted atraumatic chromic catgut sutures [Figure 5]. Then skin closure was done by vertical mattress suturing with 1-0 mersilk suture [Figure 6]. A pressure dressing was done to reduce the incidence of hematoma formation. The patient was instructed for routine wound care and wound was checked daily for 2-7 days. The suture was removed after 7 days and follow-up was done up to 2 months at 7-day interval.

## 3. RESULTS

The wound was completely healed. There was no pain and inflammation at the site of excision. At last, patient was completely freed from disfigurement due to subcutaneous lipoma.

## 4. DISCUSSION

Lipomas, which make up about 16% of soft tissue mesenchymal tumors and include lipo fibromatous hamartoma and hemangioma, are tumors with non-neural genesis.<sup>[6]</sup> They are divided into 9 different categories including lipoma, lipomatosis, lipomatosis of the nerve, lipoblastoma, angioliipoma, myoliipoma of soft tissue, chondroid lipoma, pleomorphic/spindle cell lipoma, and hibernoma by the 2002 World Health Organization Committee for the classification of soft-tissue tumors. They are not common in hand and rare in forearm, especially subcutaneous or encapsulated lipoma.<sup>[7]</sup> These sparsely encapsulated tumors are made up of mature fatty tissue, where typical signet ring cell is formed by the core lipid droplet and peripherally positioned nucleus.<sup>[8]</sup> They develop from primitive fatty tissue cells of the mesenchyme. These tumors could emerge from the subcutaneous tissue superficially.

Clinically, superficial lipomas frequently present as a slow growing, soft variant, bulging, lobulated, and movable mass that causes no symptoms. They produce pain, distal sensory alterations, and motor dysfunction unless they are frequently linked to nerve compression.<sup>[9]</sup> Due to their expanding size, they may hinder mobility and impair function. Contrary to deep lipomas, for which clinical evaluation merely shows a vague mass. Superficial lipomas can be accurately diagnosed in up to 85% of cases.<sup>[10]</sup> To prevent recurrence, careful

dissection is required throughout the surgical operation. After marginal excision, recurrence is <5%.

In this case, tumor was subcutaneously placed. The original diagnosis was confirmed by a histological examination that revealed a yellowish, lobulated ulcerative lipoma. There are no complications that occurred during post-operative period while the patient achieved free motion with no disfigurement. No recurrence was done during follow-up period. It is one of the treatments of choice as surgical excision of neoplasm with resection was performed duly with no post-operative complication.

## 5. CONCLUSION

Although subcutaneous or encapsulated lipoma is rare in forearm, it is important to be aware of those lipomas because those have a wide differential diagnosis from other soft-tissue tumors and from the specific subtypes involved.

## 6. ACKNOWLEDGMENT

I would like to acknowledge and give my warmest thanks to my supervisor Prof. (Dr.) Ranjan Kumar Kasta who made this work possible. His support and guidance carried me through all the stages of writing my project. I would like to thank my all lectures, seniors, juniors, and batchmates of my department for letting my defense be an enjoyable moment and for their brilliant suggestions and comments.

I would like give my special thanks to my family for their continuous support and understanding me very well. Their love and blessings for me were what sustained me this much.

At last, I would like to pay my gratitude to Lord Jagannath for letting me through all difficulties. I have gained experience due to your guidance day by day. You are the one for whom, I am standing here. I must keep on trusting you for my future.

## 7. AUTHORS' CONTRIBUTIONS

All the authors contributed equally in design and execution of the article.

## 8. FUNDING

Nil.

## 9. ETHICAL APPROVALS

This study has not required ethical clearance as it is case study.

## 10. CONFLICTS OF INTEREST

Nil.

## 11. DATA AVAILABILITY

This is an original manuscript and all data are available for only review purposes from principal investigators.

## 12. PUBLISHERS NOTE

This journal remains neutral with regard to jurisdictional claims in published institutional affiliation.

**REFERENCES**

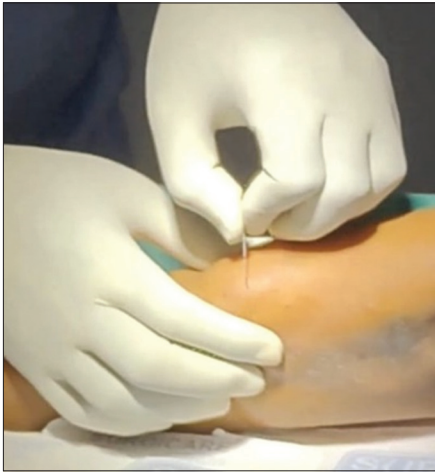1. Enzinger FM, Weiss SW. Soft Tissue Tumors. St. Louis: Mosby; 1995. p. 381-430.3.
2. Terzioglu A, Tuncali D, Yuksel A, Bingul F, Aslan G. Giant lipomas: A series of 12 consecutive cases and a giant liposarcoma of the thigh. *Dermatol Surg* 2004;30:463-7.
3. Choi CW, Kim BJ, Moon SE, Youn SW, Park KC, Huh CH. Treatment of lipomas assisted with tumescent liposuction. *J Eur Acad Dermatol Venereol* 2007;21:243-6.
4. Powell B, Mclean NR. The treatment of lipomas by the "squeeze" technique. *J R Coll Surg Edinb* 1985;30:391-2.
5. Kenawi MM. "Squeeze delivery" excision of subcutaneous lipoma related to anatomic site. *Br J Surg* 1995;82:1649-50.
6. Ersozlu S, Ozgur AF, Tandogan RH. Lipoma of the index finger. *Dermatol Surg* 2007;33:382-4.
7. Christopher D, Unni K, Mertens F. Adipocytic Tumors. WHO Classification of Tumors. Pathology and Genetics: Tumors of Soft Tissue and Bone. Lyon, France: IARC; 2002. p. 19-46.
8. Calandruccio JH, Jobe MT. Campbell Operative Orthopedics. Edited by: Canale ST. Vol. 4. St. Louis: Mosby- Year Book, Inc.; 1998. p. 3704-5.9.
9. Kalisman M, Dolich BH. Infiltrating lipoma of the proper digital nerves. *J Hand Surg Am* 1982;7:401-3.
10. Murphey MD, Carroll JF, Flemming DJ, Pope TL, Gannon FH, Kransdorf MJ. Benign musculoskeletal lipomatous lesions. *Radiographics* 2004;24:1433-66.

**How to cite this article:**

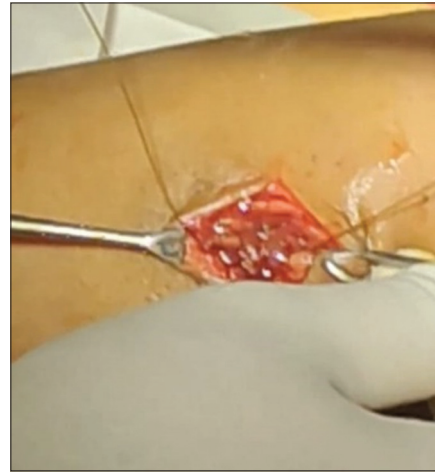
Khuntia J, Kasta RK. Lipoma of Left Forearm – A Case Report. *IRJAY*. [online] 2023;6(10):47-53.

**Available from:** <https://irjay.com>

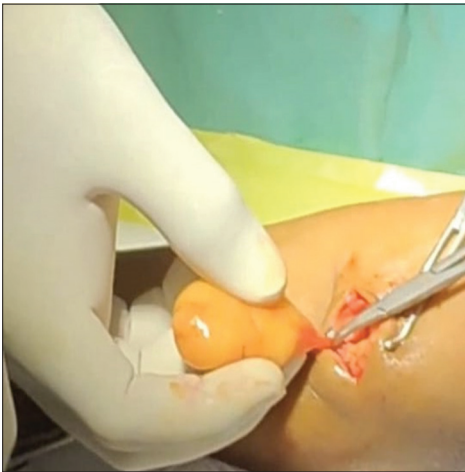
**DOI link-** <https://doi.org/10.47223/IRJAY.2023.61008>



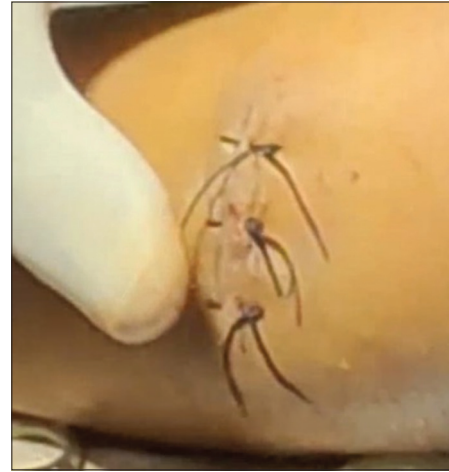**Figure 1:** Incision given prior to surgery



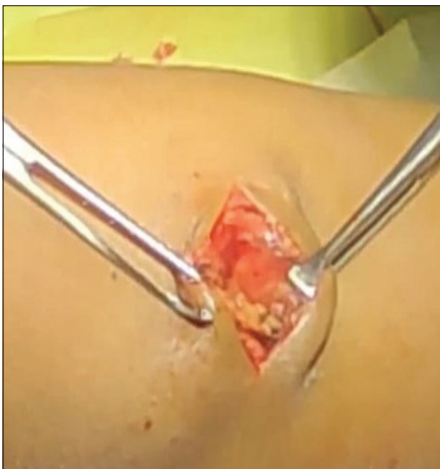
**Figure 4:** The dead space under the skin sutured by interrupted suturing



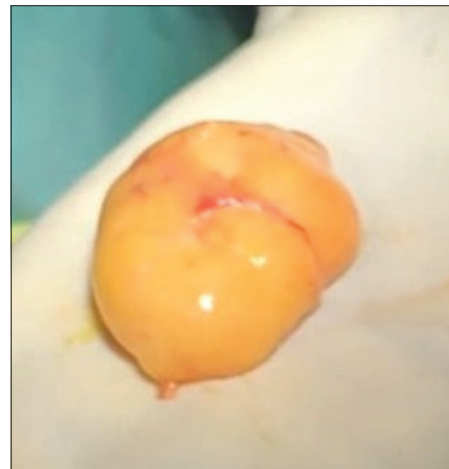
**Figure 2:** Dissection performed under lipoma



**Figure 5:** Skin closure by vertical mattress suturing



**Figure 3:** Central island of skin to be excised




**Figure 6:** Lipoma delivered as a whole


N. B.: Here, I have attached the investigation reports below.

**INVESTIGATION REPORTS**

**Investigation before Treatment**



Regd. No. 17/ 1998



Certificate No. M-0857  
NABL (03/19/03/2018)


**CURE WELL LABORATORY**  
NABL ACCREDITED  
Mangalabag, Kathagola Road, Cuttack-1

Ph.: (0671) 2306114 / 2306344  
Fax : (0671) -2306115  
E-mail : cure\_well@yahoo.com  
Website : www.curewell.info


Name : Mrs. Sonalika Pradhan  
Age/Sex : 38Yrs/Female  
Patient ID : 200070  
Sample ID :

Referral :  
Sample Coll. Time: 18/08/2023, 09:42 a.m.  
Registration Time: 18/08/2023, 09:42 a.m.  
Reporting Time : 18/08/2023, 05:30 p.m.




20230818000205689


Test Particulars	Results	Units	Biological Reference Range
<b>HAEMATOLOGY-REPORT</b>			
Hb	12.4	gm%	Male: 12-16 gm% Female: 11-14 gm% Child: 12-18 gm%
TLC	9,800	/cu.mm	4000 – 11000/cu mm
ESR	15	mm	Male: 5-10 mm Female: 5-15 mm
BT	1.20	min/sec	1-5 min/sec
CT	3.20	min/sec	3-8 min/sec
<b>Differential Leucocytes Count</b>			
Neutrophil	55	%	50-70 %.
Eosinophil	05	%	0-6 %
Basophil	00	%	0-1%
Monocyte	01	%	2-8%
Lymphocytes	39	%	15-40%
<b>SEROLOGY-REPORT</b>			
HBSAg	Negative		
HIV	Negative		
<b>BIOCHEMISTRY-REPORT</b>			
F.B.S.	100	mg/dl	70-110 mg/dl
P.P.B.S.	135	mg/dl	Up to 140 mg/dl




----- END OF REPORT -----


Dr. S. Panda, M.D. (Bio)  
Biochemist

Dr. Shreekant Tiwari, M.D. (Micro)  
Microbiologist

Dr. Sasmita Panda, M.D. (Path.)  
Pathologist


  

Dr. (Mrs.) Basanti Mishra, M.D. (Path. & Bact.)  
Chief Pathologist

• The results of the Supplied Sample are dependant upon the quality of the sample received in the lab.  
• The results should be clinically correlated and the unexpected result may be repeated.

Blood Test Report



 		<b>CURE WELL LABORATORY</b> <b>NABL ACCREDITED</b> Mangalabag, Kathagola Road, Cuttack-1		Ph.: (0671) 2306114 / 2806344 Fax : (0671) -2306115 E-mail : cure_well@yahoo.com Website : www.curewell.info
Name	: Mrs. Sonalika Pradhan	Referral :		
Age/Sex	: 38Yrs/Female	Sample Coll. Time:	18/08/2023, 09:50 a.m.	
Patient ID	: 200070	Registration Time:	18/08/2023, 09:50 a.m.	
Sample ID	:	Reporting Time	: 25/08/2023, 04:30 p.m.	
	 20230818000205690			
Test Particulars	Results	Units	Biological Reference Range	

### FNAC REPORT

**SITE OF FNAC :** Swelling over left forearm

**MICROSCOPIC EXAMINATION :**

A well-defined oval shaped homogenous mixed echogenic solid and soft tissue benign tumor of size 4.8×2.5 cm is noted in subcutaneous plain of upper left forearm with no evidence of intra lesions calcifications/hemorrhage/necrosis noted.

- Rest of soft tissue plains and intermuscular septa appears within normal limits. Surrounding adipose tissue or fat is normal. NO evidence of any focal collection.

### **SUBCUTANEOUS LIPOMA**



  
Dr. S. Panda, M.D. (Bio)  
Biochemist

  
Dr. Shreekant Tiwari, M.D. (Micro)  
Microbiologist

  
Dr. Sasmita Panda, M.D. (Path.)  
Pathologist


  
Dr. (Mrs.) Basanti Mishra, M.D. (Path. & Bact.)  
Chief Pathologist

- The results of the Supplied Sample are dependant upon the quality of the sample received in the lab.
- The results should be clinically correlated and the unexpected result may be repeated.


Prince Line

FNAC Report

Investigation After Treatment



Regd. No. 17/ F886



CHARTERED No. M/0857  
NABL ISO 15189:2013

## CURE WELL LABORATORY

NABL ACCREDITED


Mangalabag, Kathagola Road, Cuttack-1

Ph : (0671) 2306114 / 2306344

Fax : (0671) -2306115

E-mail : cure\_well@yahoo.com

Website : www.curewell.info

Name	: Mrs. Sonalika Pradhan	Referral :	
Age/Sex	: 38Yrs/Female	Sample Coll. Time:	27/08/2023, 04:20 p.m.
Patient ID	: 200210	Registration Time:	27/08/2023, 04:40 p.m.
Sample ID	: 	Reporting Time	: 05/09/2023, 03:15 p.m.

Test Particulars	Results	Units	Biological Reference Range
------------------	---------	-------	----------------------------

HISTO-PATHOLOGY REPORT

Histopathological findings are denoting the followings :

Diagnosis :

'Subcutaneous nodule', biopsy :  
-Mature adipose tissue

Comment :

Immunostaining for MDM2 marker shows negative result.



 Dr. S. Panda, M.D. (Bio) <small>Biochemist</small>	 Dr. Shreekant Tiwari, M.D. (Micro) <small>Microbiologist</small>	 Dr. Sasmita Panda, M.D. (Path.) <small>Pathologist</small>	 Dr. (Mrs.) Basanti Mishra, M.D. (Path. & Bact.) <small>Chief Pathologist</small>
--	--	--	--

- The results of the Supplied Sample are dependant upon the quality of the sample received in the lab.
- The results should be clinically correlated and the unexpected result may be repeated.

Histo-pathology Report