

---

Submitted : 05-07-2016

Accepted : 21-08-2016

Published : 15-10-2016

### Immunomodulatory Effect of *Andrographis paniculata* during Lead Induced Toxicity in Broilers

A. S. Chandewar, R. S. Ingole, M. V. Joshi, Madhuri Hedau, S. W. Hajare and M. V. Ingawale

Department of Pharmacology & Toxicology

PGIVAS, Akola- 444 104 (M.S.)

Corresponding Author : [ingoleranjit@rediffmail.com](mailto:ingoleranjit@rediffmail.com)

---

This work is licensed under the Creative Commons Attribution International License (<http://creativecommons.org/licenses/by/4.0/P>), which permits unrestricted use, distribution and reproduction in any medium, provided the original work is properly cited.

---

Copyright ©: 2016 by authors and SVSBT.

#### Abstract

The effect of dietary lead exposure on immunomodulation of broilers and possible ameliorative effect of *Andrographis paniculata* were studied. One hundred broiler chicks were randomly divided into five equal groups of 20 each. Group T0 served as control while group T1, T2, T3 and T4 birds were provided commercial diet with lead acetate at the dose of 300 ppm in feed. Powder of dry leaves of *Andrographis paniculata* was mixed in the feed of group T2, T3 and T4 chicks at the dose of 2 gm, 3 gm and 4 gm/kg of feed respectively and fed for 4 weeks. Significant decrease in HI titres in T1 group and significant increase in T4 group suggested increased haemagglutination titre (HI) response. The maximum skin thickness and diameter on 24<sup>th</sup> and 48<sup>th</sup> hours was observed in control group birds (T0) and was comparable with T4 group. Microscopically spleen, thymus and bursa of fabricius revealed increase in lymphoid population in birds fed lead acetate along with *Andrographis paniculata* compared to T1 group. We concluded that *Andrographis paniculata* has immunomodulatory effect during lead toxicity in broilers.

**Key words:** Lead acetate, *Andrographis paniculata*, Immunomodulation, Broilers

#### Introduction

Most of the environmental pollutants/ metals are not only hazardous to surrounding living organisms but can also enter into the human food chain, which need serious attention. Among 275 hazardous substances (ATSDR, 2003) lead is the second most hazardous substance present in environment as an important pollutant which exerts the adverse effect in animal kingdom with clinical signs of nervous system, gastrointestinal and hematopoietic system which may ultimately causes immune dysfunction and oxidative damage (Radostits, *et al.*, 2003). The immunotoxic effect of lead have been extensively studied in animals, however, the information on its immunopathological effect in birds is scanty. According to Mateo *et al.* (2003) lead has a potential to induce oxidative stress through oxidative tissue damage (Gurer and Ercal, 2000; Ercal *et al.*, 2001) which may be prevented by an enzymatic defense system (antioxidant enzymes) and free radical scavengers (Ibitoye *et al.*, 2011).

Medicinal plants are part and parcel of human society to combat diseases, from the dawn of civilization. *Andrographis paniculata* is an herbaceous plant of family Acanthaceae, genus *Andrographis*

native to India and Srilanka and is widely cultivated in southern Asia. Mostly leaves and roots were used for medicinal purposes such as traditional siddha and ayurvedic system of medicine in India (Sharma and Joshi, 2011). The plant *Andrographis paniculata* exhibits antifungal (Nidiry *et al.*, 2015), antioxidants (Aliyu *et al.*, 2009), anti-inflammatory (Radhika *et al.*, 2009), anti-snake venom (Meenatchisundaram *et al.*, 2009) analgesic and antipyretic (Dhiman *et al.*, 2012) properties. Literature reviewed however did not reveal much more information related to experimental studies on use of *Andrographis paniculata* during lead toxicity and was found to be scanty. Hence considering the fact this study was conducted to evaluate the effect of dry leaves powder of *Andrographis paniculata*, an antioxidant in ameliorating the inhibitory effect of dietary lead acetate on immunity of broiler birds.

## Materials and Methods

For the present investigations, one hundred day old broiler chicks were procured from Khadkeshwar Hatcheries Ltd, Aurangabad and were maintained under identical condition for one week to acclimatize prior to start of experiment. After completion of first week, birds were divided into five equal groups of 20 each. Group I birds (T0) served as control, group II, III, IV and V (T1, T2, T3 and T4) were administered lead acetate at the dose of 300 ppm in feed. In addition to lead acetate group T2, T3 and T4 were given powder of dry leaves of *Andrographis paniculata* at the dose of 2 gm/kg, 3 gm/kg and 4 gm/kg of feed, respectively for an experimental period of 4 weeks to evaluate its protective effect against lead toxicity. All the birds were maintained under identical managerial conditions for a period of four week.

Both humoral and cell mediated immune responses were evaluated in each group. Serum samples from six birds of each group were collected on 14<sup>th</sup> day after post vaccination of birds by Lasota strain of New Castle Disease virus. Humoral immune responses were evaluated on the basis of HI titres against New Castle Disease viral antigen (LaSota strain) by beta procedure (i.e. constant virus, diluted serum) described by OIE (2002) utilizing 4 unit of haemagglutination (HA) of LaSota strain. Cell mediated immune responses were evaluated in six birds of each group by skin hypersensitivity test as per Jayaramu *et al.* (1981) using 1% solution of 2, 4-Dinitrochlorobenzene (DNCB) in acetone vehicle. The thickness and diameter of skin lesions were measured at 0, 24 and 48 hours after challenging with DNBCB solution using vernier calipper at the site of challenge indicating zone of reaction. Tissues of spleen, thymus and bursa of fabricius were collected in 10% formal saline solution and processed for histopathological examination by routine method. The data was analyzed by equal CRD and equal two way factorial CRD as described by Snedecor and Cochran (1989).

## Results and Discussion

Humoral immune response (HIR) in control and treatment group birds was evaluated on 14<sup>th</sup> day after post vaccination by Lasota strain of New Castle Disease virus. Significant ( $P < 0.05$ ) decrease in average log values of HI titres (Table 1) was observed in T1 group given lead acetate alone whereas significant increase in HI titres was recorded in T4 group suggesting immunomodulatory effect of *Andrographis paniculata* in broilers @ 4 gm/kg of feed. The HI titres of group T2 and T3 were comparable with control group birds. Lowest HI titers in T1 group could be possibly due to decrease in number of IgM producing cells of spleen and also decrease in secondary immune response during lead toxicity. Rahman and Joshi (2010) also reported low HI titre in experimental lead toxicity in broilers @ 250 and 400 ppm and recorded dose dependant toxic effect of lead acetate on immune system causing suppression of humoral immune response. Present findings of T1 group are in accordance with Wagh (2006) and Brahmankar *et al.* (2011) suggesting immunosuppression during lead toxicity. The present findings of increase in HI titre in group T4 are in collaboration with Mathivanan and Kalairasi (2007). The increase in HI titre in group T4 might be due to enzymatic defense system (antioxidant enzymes) and free radical scavengers (antioxidants) of *Andrographis paniculata* (Ibitoye *et al.*, 2011).

**Table 1: Average Haemagglutination Inhibition titre in different groups (Mean + SE) at the end of experiment.**

	Treatment groups					
	T0	T1	T2	T3	T4	
HI titres	6.33 <sup>b</sup> ± 0.21	5.17 <sup>c</sup> ± 0.27	5.83 <sup>b</sup> ± 0.17	5.83 <sup>b</sup> ± 0.12	7.50 <sup>a</sup> ± 0.22	CD for treatment = 0.543 (significant at 5% level)

**Table 2: Biometry of skin thickness and diameter of spreading lesions (Mean + SE) during Cell Mediate Immune Response.**

Group	Thickness of Skin (mm)			Diameter of spreading lesions (cm)		
	0	24	48	0	24	48
T0	1.06 ± 0.04	3.08 <sup>a</sup> ± 0.06	2.02 <sup>a</sup> ± 0.06	1.21 ± 0.01	2.94 <sup>a</sup> ± 0.09	1.92 <sup>a</sup> ± 0.08
T1	1.11 ± 0.05	2.19 <sup>c</sup> ± 0.19	1.61 <sup>b</sup> ± 0.11	1.18 ± 0.02	2.03 <sup>c</sup> ± 0.09	1.49 <sup>d</sup> ± 0.04
T2	1.09 ± 0.04	2.53 <sup>bc</sup> ± 0.17	1.77 <sup>ab</sup> ± 0.11	1.19 ± 0.02	2.55 <sup>b</sup> ± 0.08	1.71 <sup>bc</sup> ± 0.08
T3	1.07 ± 0.19	2.25 <sup>c</sup> ± 0.14	1.67 <sup>b</sup> ± 0.10	1.19 ± 0.02	2.24 <sup>c</sup> ± 0.11	1.57 <sup>cd</sup> ± 0.05
T4	1.09 ± 0.05	2.76 <sup>ab</sup> ± 0.17	1.83 <sup>ab</sup> ± 0.08	1.20 ± 0.01	2.72 <sup>ab</sup> ± 0.10	1.82 <sup>ab</sup> ± 0.08
CD	NS	CD for treatment = 0.452 (significant at 5% level)	CD for treatment = 0.275 (significant at 5% level)	NS	CD for treatment = 0.273 (significant at 5% level)	CD for treatment = 0.194 (significant at 5% level)

*Mean values with common alphabet as superscript do not differ significantly*

Cell mediated immune (CMI) responses were evaluated by thickness and diameter of skin lesions at the site of challenge indicating zone of reaction at 0, 24 and 48 hours after challenging with DNCB. Maximum skin thickness (mm) and diameter area (cm) was observed at 24 hours post challenge in all treatment group birds. The lowest skin thickness and diameter was observed in T1 group birds administered lead acetate alone at the dose of 300 ppm indicating suppression of cell mediated immune response during lead toxicity (Table 2). Lead induced apoptosis of lymphocytes or altered T cell activity in birds might be the reason for decreased CMI response in

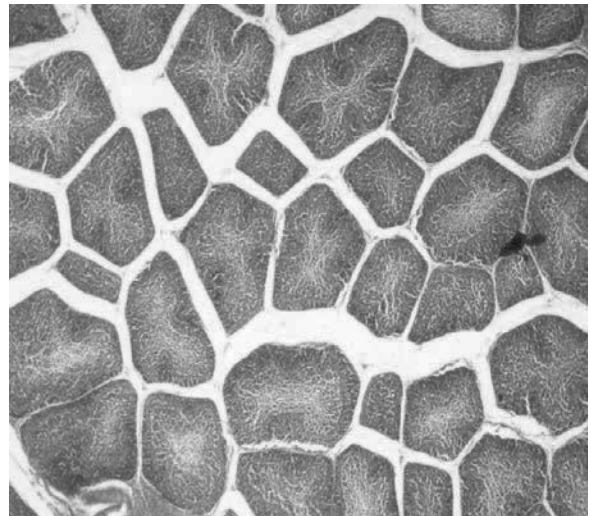
lead toxicity (Shukla *et al.*, 2004). Differences in skin thickness and diameter between control and treatment T1, T2 and T3 group birds at 24 and 48 hours were found to be statistically significant. The maximum skin thickness and diameter was observed in control group but was comparable with T4 group showed improvement in cell mediated response in birds given *Andrographis paniculata* @ 4 gm/kg of feed. Bukoye and Musbau (2011) also recorded immune modulation potential of the aqueous extract of *Andrographis paniculata* @ 250, 500 and 1000 mg/kg BW in male rats confirm the present findings.

Histologically, the sections of spleen, thymus and bursa from control group birds showed uniform cellularity with normal lymphoid population (Fig: 1) however, T1 group birds showed depletion in lymphoid populations (Fig: 2) as compared to control group birds. Present findings are in collaboration with Rahman and Joshi (2010) in broilers confirming lead toxicity in T1 group. Restoration in lymphoid nodules with adequate lymphoid population was observed in sections from T4 group birds (Fig:3) followed by T3 and T2 suggested immunomodulatory effect of *Andrographis paniculata* in broilers which might be due to protective mechanism such as an enzymatic defense system (antioxidant enzymes) and antioxidants property of *Andrographis paniculata* (Ibitoye *et al.*, 2011). Comparatively decreased size of follicles and depletion in lymphoid populations in T1 group might be possibly due to lead induced apoptosis of lymphocyte or altered T cell activity in birds as reported by Shukla *et al.*, (2004).

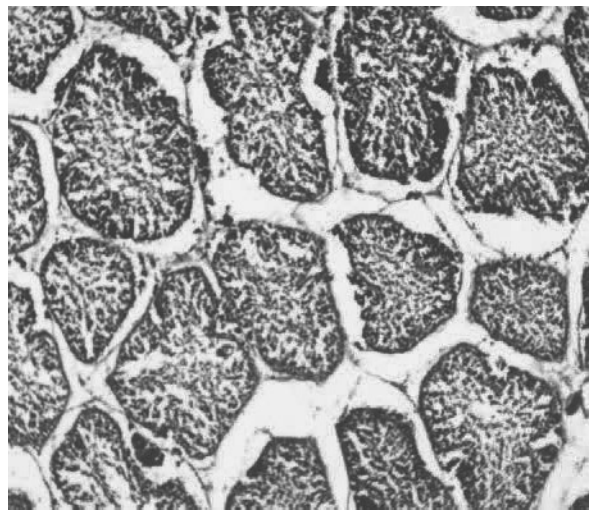
### Acknowledgements

Authors are thankful to the Department of Veterinary Pathology, Post Graduate Institute of Veterinary and Animal Sciences, Akola for providing necessary research facilities for research work.

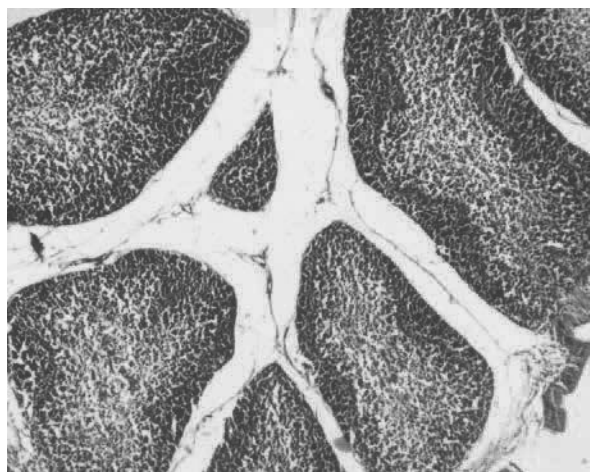
**Conflict of Interest:** All authors declare no conflict of interest.



**Fig : 1** Bursa of fabricius showing normal lymphoid population in Control group bird (H&E- x100)



**Fig : 2** Bursa of fabricius showing depletion of lymphoid population of T1 group bird (H&E- x100)



**Fig: 3** Bursa of fabricius showing comparatively normal lymphoid population in T4 group bird (H&E- x200)

## References :

- Agency for Toxic Substances and Disease Registry (ATSDR) (2003) Toxicological profile for lead, US Department of Health and Human Services, Atlanta, Georgia, USA
- Aliyu, A. B., Musa, A. M., Sallau, M. S. and Oyewale, A. O. (2009). Proximate Composition, Mineral Elements and Anti-nutritional Factors of *Anisopus Mannii* N. F. Br. (Asclepiadaceae), *Trends Appl. Sci. Res.*, 4(1): 68-72.
- Brahmankar, M. G., Wagh, S. B., Kale, D. B. and Joshi, M. V. (2011). *J. of Advances in Pharmacy and Healthcare Research*.
- Bukoye, O. and Musbau, A. (2011). Immune Modulation Potentials of Aqueous Extract of *Andrographis paniculata* leaves in Male Rat. *Researcher*. 3 (1): 48-57.
- Dhiman, A., Goyal, J., Sharma, K., Nanda, A. and Dhiman, S. (2012). A review on medicinal prospective of *Andrographis paniculata* Nees. *J. Pharmaceutical and Scientific Innovation*. 1(1): 1-4.
- Ercal, N., Gurer-Orhan, H. and Aykin-Burns, N. (2001). Toxic metals and oxidative stress. Part I: Mechanism involved in metals induced oxidative damage. *Current Topics Medicinal Chemistry*. 1: 529-539.
- Gurer, H. and Ercal, N. (2000). Can antioxidants be beneficial in the treatment of lead poisoning? *Free Radical Biology and Medicine*. 29: 927-945.
- Ibitoye, E. B., Oloredo, B. R., Agaie, B. M., Ahmed, A. and Jimoh, A. A. (2011). Effect of dietary lead exposure and graded levels of ascorbic acid supplementation on performance and hematology of broiler chickens. *Sokoto J. Veterinary Sciences*. 9(2): 1-6.
- Jayaramu, G. M., Satyanarayana, M. L., Ravikumar, P. and Narayanswami, H. D. (2012). Evaluation of the immune status of broiler chicken during ochratoxin, citrinin and their combined toxicity. *International J. of Advanced Biological Research*. 2(4): 756-759.
- Mateo, R., Beyer, W. N., Spann, J. W. Hoffman, D. J. and Ramis, A. (2003). Relationship between oxidative stress, pathology and behavioral sings of lead poisoning in mallards. *Journal of Toxicology and Environment Health A*. 66: 1371.
- Mathivanan, R. and Kalairasi, K. (2007). Panchgavya and *Andrographis paniculata* as alternatives to antibiotic growth promoters on haematological, serum biochemical parameters and immune status of broilers. *The J. of poultry Sci*. 44: 198-204.
- Meenatchisundaram, S., Parameswari, G. and Michael, A. (2009). Studies on antivenom activity of *Andrographis paniculata* and *Aristolochia indica* plant extracts against *Daboia russelli* venom by in vivo and in vitro methods. *Ind. J. of Sci. and Tech*. 2(4): 1-4.
- Nidiry, E. S. J., Ganeshan, G., Lokesh, A.N. (2015). Antifungal activity of the extract of *Andrographis paniculata* and andrographolide. *Journal of Pharmacognosy and Phytochemistry*. 4(2): 08-10.
- OIE. (2002). Office International Des Epizooties. Manual of Standards for Diagnostic Tests and Vaccines. 4th Eds., Paris, France
- Radhika P., Prasad R. Y., Sastry B.S. and Rajya L. K. (2009). Anti-inflammatory Activity of Chloroform Extract of *Andrographis Paniculata* Nees Stem. *Res. J. Biotech*. 4(2): 1-4.
- Radostits, D. M., Gay, C. C., Blood, D. C. and Hinchcliff, K. W. (2003). Diseases caused by inorganic poisons. In: *Veterinary Medicine*. 9<sup>th</sup> Edn. Book Power (Formerly ELST): 1575-1585.
- Rahman, S. and Joshi, M. V. (2010). Immunopathological effect of lead acetate on humoral and cell mediated immune responses in broilers. *Tamilnadu J. Veterinary & Animal Sciences*. 6 (4): 157-161.
- Sharma, M. and Joshi, S. (2011). Comparison of anti-oxidant activity of *Andrographis paniculata* and *Tinospora cordifolia* levels. *J. Curr. Chem. Pharm. Sc*. 1(1): 1-8.
- Shukla, G., Singhal, L.K., Singh, D.D., Kumarand, R. and Chauhan, R. S. (2004). Lead induced apoptosis in avian lymphocytes. *J. Immunol. Immunopathol*. 6 (S-1): 106-109.
- Snedecor, G. W. and Cochran, W. G. (1989). *Statistical Methods*, 8th Ed., Iowa State Univ Press, Ames, IOWA.
- Wagh, S. B. (2006). Studies on lead toxicity in broilers with special reference to immunopathological investigations. M.V.Sc. Thesis submitted to MAFSU, Nagpur.

□