

## CASE REPORT

# Therapeutic Management of Snake Bite in a Rottweiler Dog

MJ Bharai, PG Dodiya, AA Vagh\*

**Keywords:** Anti-venom serum, Clinical management, Dog, Snakebite.

*Ind J of Vet Sci and Biotech* (2019): 10.21887/ijvsbt.15.2.24

**M**Snakebite cases are more common in horses and dogs when compared to other animals such as cattle, sheep, and goats. Snake envenomation can be difficult to diagnose if the incident was not witnessed. Clinical signs may vary greatly depending on the species of snake involved, and the quantity and toxicity of the venom injected. Dogs are commonly presented with extensive edematous swelling, severe pain, ecchymosis, and discoloration of the skin in the affected area within several hours after the bite (Garg, 2002) The animals exhibit various symptoms like cardio-pulmonary dysfunction, local tissue damage, blood coagulation defects, ataxia etc, depending on type of snake bite (Bhardwaj, 2011). Systemic signs can vary and may include hypotension, shock, cardiac arrhythmias, bleeding disorders, ptyalism, nausea, vomiting, respiratory distress, mental confusion, rhabdomyolysis, and acute renal failure (Ananda *et al.*, 2009). The snake bite with envenomation is a true emergency, and it needs rapid examination and prompt appropriate treatment. The current paper reports on the successful use of antihistamine together with anti-snake venoms, fluids, corticosteroids, and antibiotics with no untoward effects in a snake-bitten dog.

### CASE REPORT, OBSERVATIONS, AND DIAGNOSIS

A 2.5 years old male Rottweiler dog was presented to the Veterinary Clinical Complex of the College in Junagadh with a history of frothy salivation, dullness, depression, abnormal gait and pupillary dilation. According to the owner, the dog was usually placed in farm for playing in evening hours and had a history of snake problem and the dog often hunt it.

Physical examination revealed cyanotic swollen areas with fang marks, edematous swelling on the right commissar, and jaw of dog (Figures 1 and 2). Based on history and physical examination, the dog was suspected of a snake bitten. The clinical parameters like rectal temperature, pulse and respiratory rate were 102.8° F, 93/min, and 44/min, respectively. The blood sample collected from the dog with EDTA for hematological parameters revealed decreased hemoglobin concentration (6.8 g/dL) and packed cell volume (19.89 %) and increased total leukocyte count (20850/cmm). The capillary clotting time was more than 26 min.

Department of Veterinary Medicine, College of Veterinary Science and Animal Husbandry, Junagadh Agricultural University, Junagadh, Gujarat-362001, India

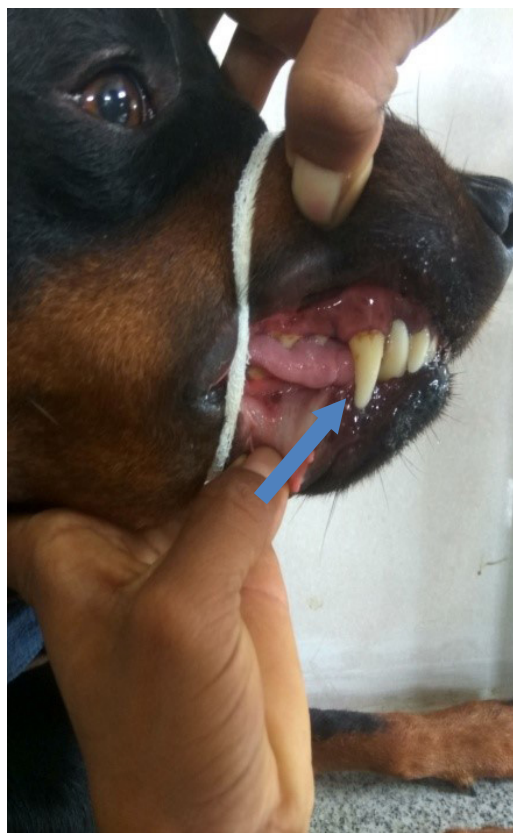
**Corresponding Author:** A.A. Vagh, Department of Veterinary Medicine, College of Veterinary Science and Animal Husbandry, Junagadh Agricultural University, Junagadh, Gujarat-362001, India, e-mail: dr\_vagh@yahoo.co.in

**How to cite this article:** Bharai, M.J., Dodiya, P.G. and Vagh, A.A. (2019). Therapeutic Management of Snake Bite in a Rottweiler Dog. *Ind J Vet Sci and Biotech*, 15(2): 83-84.

**Source of support:** Nil

**Conflict of interest:** None.

**Submitted:** 25/09/2019 **Accepted:** 04/10/2019 **Published:** 25/11/2019



**Fig.1:** Fang marks on the lower jaw



Fig. 2: Edematus swelling on the lower jaw

## TREATMENT AND DISCUSSION

The dog was treated with polyvalent anti-snake venom serum (Bharat Serums & Vaccines Limited, Thane, India, Fig. 3). Anti-snake venom serum was administered intravenously along with 250 ml of 5% dextrose, followed by Dexamethasone at the dose of 2 mg/kg body weight and Atropine sulfate at the rate of 0.02 mg/kg intramuscularly. Chlorpheniramine maleate 2 ml and Botrophase 1 mL were also given intravenously. Besides, Ceftriaxone at the dose of 20 mg/kg, s/c, and tetanus toxoid 2 mL i/m were also given. After 1 hour, it was observed that the dog was passing blood in the urine. After 5 hours, the dog was active with yellow color urine, and there was no relapse of the signs. The antibiotic therapy was continued for 5 days along with liver tonic. After one week of treatment, it was confirmed that the dog was recovered uneventfully.

Snake venoms are complex mixtures of proteins and peptides, consisting of both enzymatic and non-enzymatic compounds. Snake venoms also contain inorganic cations such as sodium, calcium, potassium, magnesium, and small amounts of zinc, iron, cobalt, manganese, and nickel. The other components of snake venoms are glycoproteins, lipids, and biogenic amines, such as histamine, serotonin and neurotransmitters (catecholamines and acetylcholine) (Klaassen, 2008). Clinical signs such as frothy salivation, dullness, muscular weakness with abnormal gait observed in the present study could be attributed to the enzymatic and non-enzymatic compounds in the snake venom. Hyaluronidase cleaves internal glycoside bonds in certain acid mucopolysaccharides resulting decreased viscosity of connective tissues allowing other fractions of venom to penetrate the tissues. The cyanotic edema observed at the site of bite may be attributed to enzyme hyaluronidase, which acts as a spreading factor (Klaassen, 2008). The alterations in the hematological parameters might be due to damage to the blood cells by snake venom (O'Shea, 2005). Sometimes lyophilized polyvalent anti-snake venom may cause anaphylactic reactions (Sai Butacha Rao *et al.*, 2008) so to overcome the untoward effect of antivenom serum;



Fig. 3: Administration of Anti-snake venom

dexamethasone injections are given to the patient. However, in the present study, corticosteroid was preferred over antihistamines as, in certain cases, it potentiates the toxic action of the snake venom (Singh, 1980). Prophylactically, tetanus toxoid and broad-spectrum antibiotics were administered to the dog, as the fangs of the snake are supposed to be contaminated with various types of bacteria.

In summary, clinical observations of a 2.5-year old Rottweiler dog with the history of frothy salivation, red-colored urine, abnormal gait, and papillary dilatation, depicted fang marks and oedematous swelling on the lower jaw, which prompted to diagnose it as viper bite, and was successfully treated with anti-snake venom serum along with supportive therapy.

## ACKNOWLEDGMENT

We thank the Dean of Veterinary College, JAU, Junagadh for the facilities provided.

## REFERENCES

- Ananda, K.J., Mohan, K., Ansar, K., Sharada, R. (2009). Snake bite in dogs and its successful management. *Vet. World*, 2: 66-67.
- Bhardwaj, R.K. (2011). Clinico-haematobiochemical and therapeutic management of snake bite in canines. *Intas Polivet*, 12(2): 204-205.
- Garg, S.K. (2002). Zootoxins. In: *Veterinary Toxicology*. 1<sup>st</sup> Edn, CBS publishers and Distributers, New Delhi, India.
- Klaassen, C.D. (2008): Properties and Toxicities of Animal Venoms. In: *Toxicology*. 7<sup>th</sup> Edn, McGraw-Hill, New Delhi, India, pp 1093-1098.
- O'Shea, M. (2005): *Venomous Snakes of the World*. Princeton: Princeton University Press.
- Sai Butcha Rao, Satish Kumar M. and Thirumala Rao, D.S. (2008): Therapeutic management of snake bite in a dog. *Intas Polivet*, 9(1): 116.
- Singh, B. (1980): Snakes, snake bite symptoms, diagnosis and treatment. *Livestock Advisor*, 5: 55-60.