

**Indian Internet Journal of Forensic
Medicine and Toxicology**
Year 2025, Volume-23, Issue-2 (Jul-Dec)



A Case Report of Physical Assault and Traumatic Mechanical Injuries Report to Emergency department of SRMS IMS Bhojipura Bareilly

Mohd Shariq^{1*}, Jaswinder Singh², Arsh Aggarwal³, Vijay Kumar⁴, Vinod Gupta⁵

^{1*}Tutor, Department of Forensic Medicine and Toxicology, SRMS IMS Bhojipura Bareilly

²Professor & Head, Department of Forensic Medicine and Toxicology, SRMS IMS Bhojipura Bareilly

³Junior Resident-2, Department of Forensic Medicine and Toxicology, SRMS IMS Bhojipura Bareilly

⁴Associate professor, Department of Forensic Medicine and Toxicology, SRMS IMS Bhojipura Bareilly

⁵Assistant professor, Department of Forensic Medicine and Toxicology, SRMS IMS Bhojipura Bareilly

ARTICLE INFO

Keyword: injury; physical assault; BNS

doi: 10.48165/ijffmt.2025.23.2.8

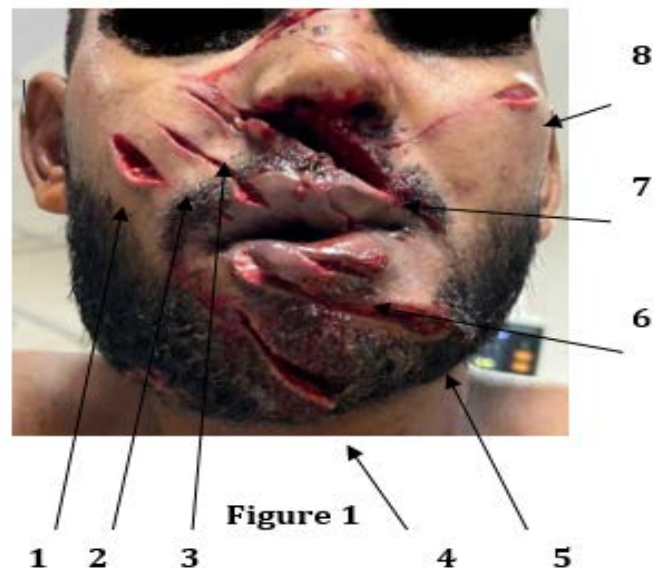
ABSTRACT

According to section 44 IPC now BNS 2(14) “the word “injury” denotes any harm whatever illegally caused to any person, in body, mind, reputation or property”^[1] clinically it is breach of natural continuity of skin or mucous membrane^[2] profound study of injuries plays a significant role in medicolegal study. This case report emphasizes the identification of injury types while ruling out alternative injury classification to prevent errors while maintaining accurate medical records.

Case report

On the fateful night of 19/11/2024 around 1 am, as per the alleged history of patient attendants, patient was involved in a physical assault with unknown person carrying unknown sharp weapon. Patient was attacked multiple times by the assailant on head and face with sharp weapon due to which he fell down on ground followed by another attack by the assailant on the back posterior side head. the patient was brought to SRMS IMS on 19/11/2024 around 2 AM in casualty in an unconscious state by attendants, with visible open injuries and clots of blood accumulated all over the head, face and body with multiple incised wounds and abrasions on face extending from the mandible region to frontal region to occipital region. Patient was immediately shifted to red triage for the further investigation and management.

A 3 cm * 1cm muscle deep incised wound in right buccal region with everted margins (**Fig.1Aarrow1**) and various surrounding incised wounds of different measurement were found. A beveled incised wound measuring 5cm *1.5cm



muscle deep (**Fig.1A4**) and 7cm*1cm muscle deep (**Fig.1A5**) was present above mental protuberance. An incised wound 8cm*1cm bone deep (**Fig.5A16**) was present on frontal region of head.

Corresponding author: Mohd Shariq

Email Address: sharikdiamond@gmail.com

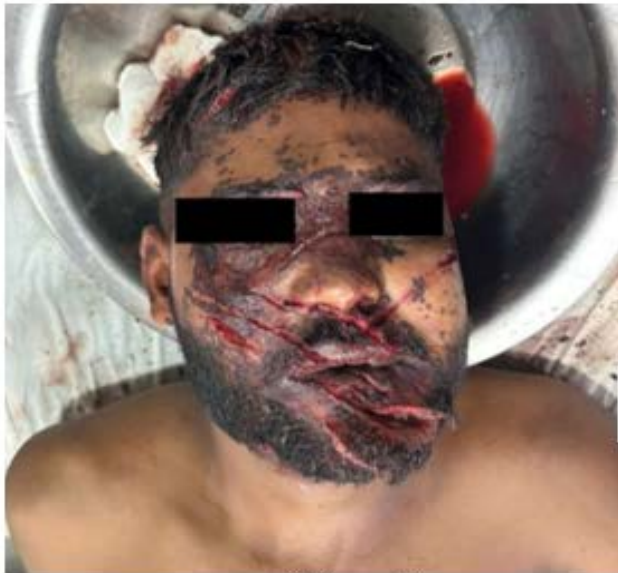

Figure 2

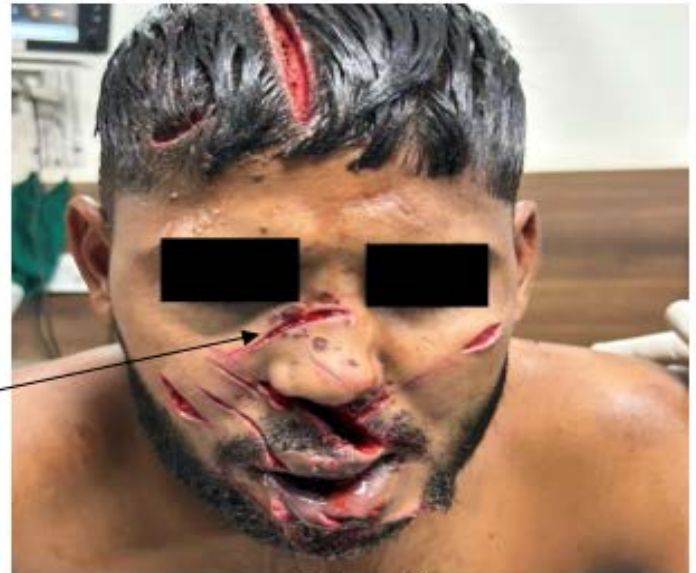

Figure 3

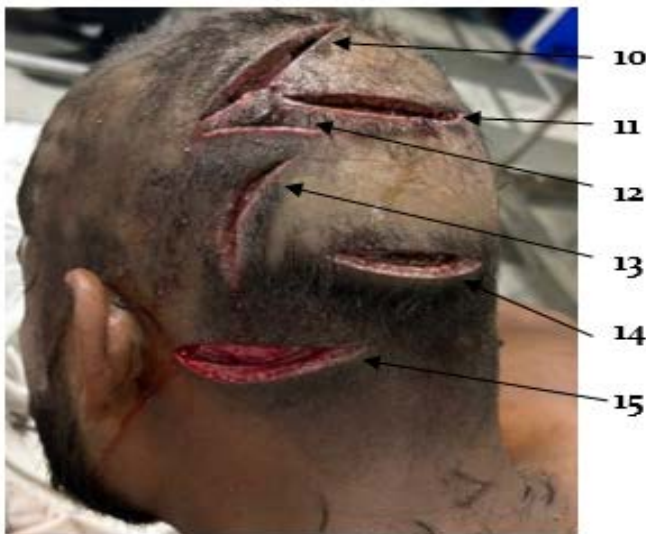

Figure 4

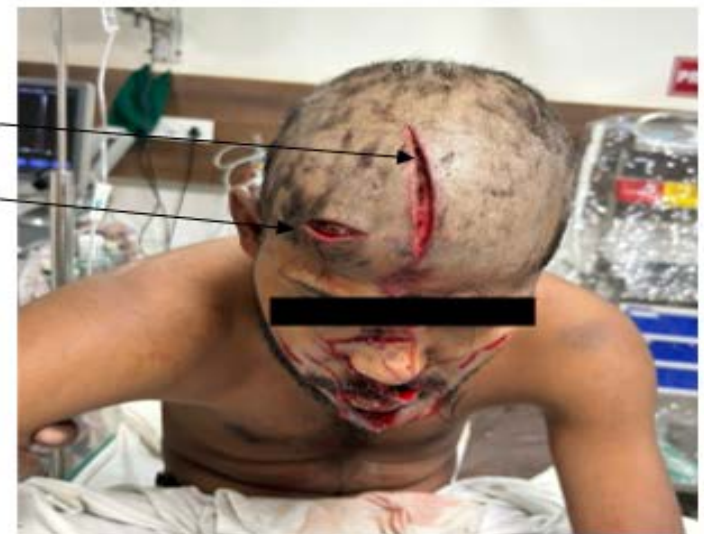

Figure 5

Discussion

The field of forensics places great attention on wound examination. Establishing a thorough and systemic wound evaluation procedure is essential [3]. Assault elementally physical assault is demarcated by wide range of injuries from Contused abrasion to Major lacerations some of them mimicking incised looking laceration, neither most is descriptive in its own terms of defining the prospects of SOPs of enlisted injuries in medicolegal case documents determined by acting physician or casualty medical officer. The Reported case of physical violence examined by us is based on detrimental approach in overall controlled studies amongst northern region. The following case approaches the demarcated injuries to be of the type “Incisional” Type; further forensic investigator approach may conclude utmost to incised looking lacerated wound. Despite visible gaping in

the injuries, multiple incisions inflicted by sharp force is the main erroneous strata conforming to the complexity of the case. Further discussion explained that rules out the injuries are: spindle shaped wound in the skin with clean, regular and usually everted margin produced by significant pressure and friction against the tissue by a sharp edge object such as knife glass or metal edge exemplify an incised wound as in figure 1-6 and arrowed marked with number 1-17. (However, margins of Incisional wound may be inverted if a small layer of muscle fibers is linked to the skin, as in the scrotum) [4].

Upon examining wound no. 1,5,7,8,9,15,16 which exhibit a spindle shaped configuration, and compare them with wound no 2,3,11,12 we notice a linear shape and minimal gaping, defies the effect of langer’s lines. When injuries are produced against langer’s lines show gaping and slow healing while incisions perpendicular to Langer’s lines have a tendency to pucker and remain obvious [5]. The presence of Gaping,

beveling, head end to fish tailing and distinct margins of injuries hold significant medicolegal importance. The long tails are due to the knife rising from the skin^[6]. The direction of the force used can then be inferred from the depth of the incised wound with tailing^[7]. These characteristics provide crucial information regarding direction of assault and the type of weapon employed during the incident.

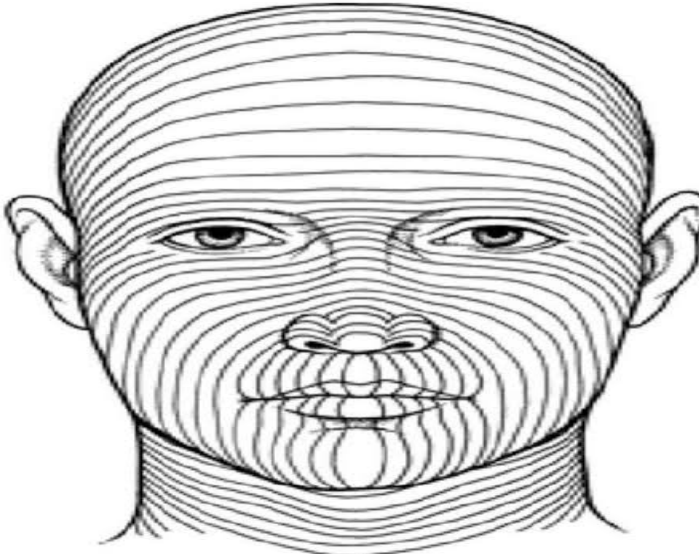


Figure 6: Langer's lines

References

- India Code. Section details [Internet]. New Delhi: Government of India; 2025 [cited 2025 Feb 13]. Available from: https://www.indiacode.nic.in/show-data?actid=accen_5_23_00037_186045_1523266765688§ion-id=45775§ionno=44&orderno=45
- Biswas G. *Review of forensic medicine and toxicology*. 6th ed. New Delhi: Jaypee Brothers Medical Publishers.
- Ohshima T. Forensic wound examination. *Forensic Sci Int*. 2000;113(1-3):153-164.
- Amira A, Abdelaal M, Omran F, Sarah S. Forensic perspective of injuries with particular focus on incised wounds. *Zagazig Univ Med J*. 2024 May 27;0(0).
- Forensic pathology [Internet]. Salt Lake City (UT): University of Utah; [cited Year not specified]. Available from: <https://webpath.med.utah.edu/FORHTML/FOR028.html>
- Saukko P, Knight B. *Knight's forensic pathology*. 4th ed. Boca Raton (FL): CRC Press; 2015. p. 154-155.
- Biswas G. *Review of forensic medicine and toxicology*. New Delhi: JP Medical Ltd; 2015. p. 188-189.