

## Case Report

# An Unusual Intravesical Foreign Body – Erotogenic Masochism with a Brief Review

Saini OP<sup>1</sup>, Saini PK<sup>1</sup>, Bohra B<sup>2\*</sup>, Mathur IB<sup>2</sup>

<sup>1</sup>Assistant Professor, <sup>2</sup>Residents, Department of Forensic Medicine and Toxicology, S.P. Medical College and A.G. of Hospital, Bikaner, Rajasthan

\*E-mail id: drbhabeshbohra@yahoo.co.in

### ABSTRACT

A wide range of unusual foreign bodies in the bladder has been reported in the literature. The urethra is the main entrance if the foreign body is inserted into the urinary tract. We present a report regarding a Hindu male aged 16 years, who was admitted in the Urology Department of S.P. Medical College and Associated Group of Hospital, Bikaner, on 3.12.2007 with complaints of pain in the lower abdomen and blood in urine. The X-ray examination revealed a foreign body in the urinary bladder, which was removed by an urologist. The case was referred to a psychiatrist, who took the patients into confidence and diagnosed him as case erotogenic masochism.

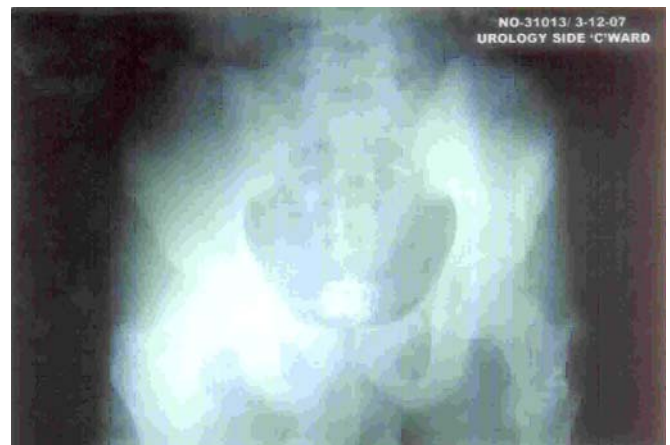**Keywords:** Intravesical Foreign Body, Masochism

### INTRODUCTION

arious foreign bodies are encountered in the bladder, such as thermometer<sup>1</sup>, thermometer tip<sup>2</sup>, tip of Foley's catheter<sup>3</sup>, aluminium rod<sup>4</sup>, battery<sup>5</sup>, fish<sup>6</sup> and plastic chopstick and magnet tube<sup>7</sup>, etc. Introduction of a foreign body into the bladder may be through self-insertion, iatrogenic means or migration from the adjacent organs. Such objects are usually inserted for eroticism, inquisitiveness (particularly in children) as a consequence of psychiatric or senile states or under the influence of alcohol. There is a marked preponderance in male patients<sup>8</sup>.

### OBSERVATION

A 16-year-old male was admitted in the urology side of our hospital on 3.12.2007 with complaints of pain in the lower abdomen and blood in urine. The boy was averagely built and had an anxious look. The X-ray examination of his abdomen revealed a foreign body in the urinary bladder (Photograph-1).



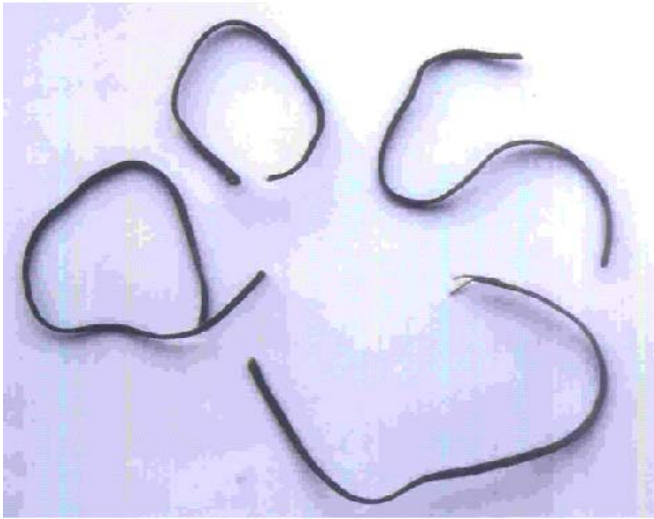
**Photograph-1**

The other parameters and investigations were normal, except the RBCs in urine. The treating doctors interrogated the foreign body. He gave the history that about 6 months back, he had a quarrel in which four boys caught him and introduced a wire. He also said that they had threatened to kill him if he narrated about the matter to his parents.

## An Unusual Intravesical Foreign Body – Erotogenic Masochism with a Brief Review

As the boy gave the history of assault, our department (Forensic Medicine and Toxicology) was informed by the urologist and we informed the police. The case was also referred to a psychiatrist.

The wire was removed by the urologist in four pieces. The wire was a plastic, flexible, flat and smooth having two flexible copper wires along the edges. Its total length was 84.5 cm (Photograph-2).



**Photograph-2**

### DISCUSSION

The history was doubtful as the chances of introducing a wire forcefully by other boys were remote that too in the male long urethra. The father of the boy was transferred from the state of incident to our state and even then the boy neither informed his father nor the treating doctor.

The boy gave history to the psychiatrist that he was frequently involved in such activity since the last 1 year for sexual pleasure. He also informed that he often consumed alcohol. The case was diagnosed as a case of erotogenic masochism.

Masochism takes its name from the activities of Leopold von Sacher-Masoch, a nineteenth century Austrian novelist whose characters derived sexual pleasure from being abused and dominated by women. According to DSM-IV-TR, a person with sexual masochism has a recurrent preoccupation with sexual urges and fantasies involving

the act of being humiliated, beaten, bound or otherwise made to suffer. Sexual masochistic properties are more common among men than women<sup>9</sup>.

In humans, masochism appears as a definite oblivious outstanding neurosis, which occurs periodically. Whereas in woman, it is more a way of life, a behaviour problem rather than neurosis<sup>10</sup>.

Urethral foreign bodies usually migrate into the bladder by being pushed further into the urethra by involuntary perineal muscle contraction. The length of passage that a foreign body migrates from the urethral meatus to the bladder is approximately 20 to 25 cm in an adult erected penis. Migration through the bulbous urethral curvature without significant injuries is surprisingly and still not sufficiently explained<sup>7</sup>. The length of the urethra in a flaccid penis is 18-20 cm<sup>11</sup>.

Diagnosis is difficult from the history as these patients rarely narrate the correct history due to fear of social embarrassment as happened in the present case where the wire remained in the bladder for 6 months. In such cases, psychiatric consultation should be done as most of the cases are associated with psychiatric problems and consultation also prevents the second incidence.

In cases with pain in the lower abdomen, the possibility of a foreign body in the bladder should be kept. Persistent foreign bodies may cause complications, such as infection, stone or fistula formation. There have been reports of patients who died due to sepsis and uraemia caused by foreign bodies in the lower urinary tract<sup>12</sup>.

### REFERENCES

1. Sharma S, Khaira NS, Ohri A et al. Thermometer in male urinary bladder cystoscopic management. *Ind Med Gazette* 2006; 160: 562-563.
2. Aspinall A. Removal of clinical thermometer from the bladder by manipulation. *Med J Aust* 1931;2:454.
3. Bhatiyani BR, Niyogi GM. A case of retained Foley's catheter tip in bladder. *Bombay Hospital J* 2008; 12: 1-2.
4. Bakshi GK, Agarwal S, Shetty SV. An unusual foreign body in the bladder. *J Post Grad Med* 2000; 46(1): 41-42.
5. Gogus C, Kilic O, Haliloglu, Gogus O. A very unusual intravesical foreign body in a male. *Int Urol Nephrol* 2002; 34(2): 203-04.

**Saini OP<sup>1</sup>, Saini PK<sup>1</sup>, Bohra B<sup>2\*</sup>, Mathur IB<sup>3</sup>**

6. Vezhaventhan G, Jeyaraman R. unusual foreign body in urinary bladder: A case report. *Internet J Urology* 2007; 4 (2).
7. Seung J, Moon, Die Hee Kim, Jae Hoon Chung et al. Unusual foreign bodies in the urinary bladder and urethra due to auto erotism. *Int. Neurouro J* Oct 2010; 14: 186-189.
8. Eckford SD, Persad RA, Brewster SF et al. Intravesical foreign bodies; five year review. *Br J Urol* 1992; 69: 41-45.
9. Sadock BJ, Sadock VA. In: Kaplan and Sadock. *Synopsis of psychiatry*, 2007; p-709.
10. Clifford Allen. *The sexual perversion and abnormalities*. 2<sup>nd</sup> ed 1951; p-100.
11. Standring S (Ed). *Gray's anatomy*, 39<sup>th</sup> ed., 2006; p-1295.
12. Sunwoo HS, Kwon CH, Kim YS et al. Five cases of foreign bodies lower urinary tract. *Korean J Urol* 1980; (21): 82-85.