

## Case Report

# Retained Fetal Bones in the Uterus Emerging as the Cause of Suicide: A Case Report

Suraj Ohal<sup>1</sup>, Monisha Pradhan<sup>2\*</sup>, Anju Rani<sup>3</sup>, Ashish Bhute<sup>4</sup>, C Behera<sup>5</sup>

<sup>1</sup>Junior Resident, <sup>2</sup>Assistant Professor, <sup>3</sup>Senior Resident, <sup>4</sup>Senior Resident, Department of Forensic Medicine and Toxicology, Maulana Azad Medical College, New Delhi, India

<sup>5</sup>Assistant Professor, Department of Forensic Medicine and Toxicology, AIIMS, New Delhi, India

E-mail id: \*monishapr@yahoo.com; <sup>1</sup>dr.suraj.ohal@gmail.com; <sup>3</sup>anjurani15@gmail.com; <sup>4</sup>ashish\_bhute@yahoo.com; <sup>5</sup>drchitta75@yahoo.co.in

### ABSTRACT

Retained fetal bones in the uterus post abortion may result in long-standing unexplained secondary infertility. We report a case of suicide of a 33-year-old woman by self-immolation. Pieces of retained fetal bones and cartilages were found unexpectedly at autopsy in the uterine cavity. The bones had been retained in the uterus for 4 years after an elective abortion. Since then she had been unable to conceive and was being treated for secondary infertility. The distress caused by the infertility led her to commit suicide. We have discussed the incidence, aetiology, pathology and complications of this rare cause of infertility.

**Keywords:** Forensic medicine, Forensic pathology, Fetal bones, Retention, Secondary infertility, Suicide

### INTRODUCTION

Infertility or inability to conceive can cause extreme distress in couples desiring a child. In many countries, a female who is childless can be socially stigmatised, which can cause considerable anxiety and even depression. Tubal defects or infection and ovulation problems are the common causes of infertility. Retention of fetal bones as a cause of infertility is rare and unexpected. However, it is a significant cause of secondary infertility after mid-trimester abortions. These retained bones are often undiagnosed and mostly found unexpectedly after or during gynaecological procedures. We are reporting a case of secondary infertility due to the retained fetal bones leading to prolonged distress and anxiety driving the deceased to the point of taking her own life.

### CASE REPORT

A 33-year old female presented to the emergency with 100% second degree thermal burns. Police investigation revealed that she had committed suicide by pouring

kerosene and setting herself on fire. There was past history of secondary infertility since 4 years for which she was taking treatment. The inability to conceive had been the reason for her alleged depression and suicide.

At autopsy, the deceased weighed 60 kg and was 158 cm in height. Externally, there were superficial to deep thermal burns of the skin involving whole body and face and singeing of scalp and body hair. There was strong smell of kerosene emanating from the body. There were no other injuries apart from the thermal burns. Internal organs showed congestive changes and no other abnormalities were found. The uterus appeared grossly normal externally weighing 78 g and 10.5 cm x 5.6 cm x 4.5 cm in size. On dissection, the uterine walls showed mild hypertrophy and measured 2.3 cm in thickness. Four pieces of bone-like hard fragments were found retained in the uterine cavity (Figure 1). The fragments were easily removed and measured 1.8 cm x 0.4 cm x 0.3 cm of average size. Histopathological examination of the recovered fragments confirmed fetal bones and cartilages

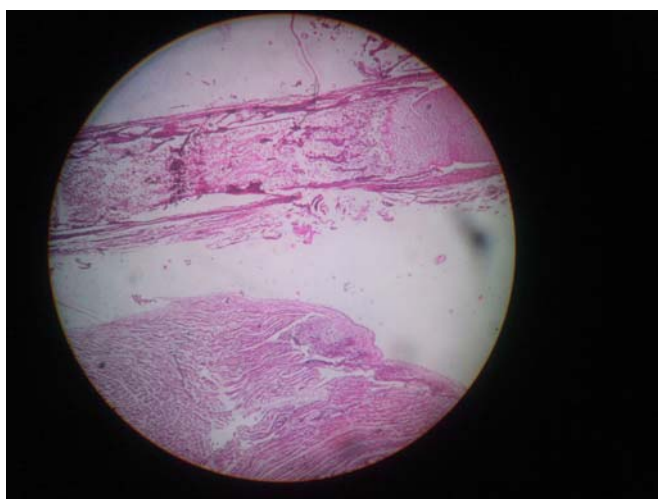
(Figures 2 and 3). The cause of death was given as shock consequent upon thermal burn injuries.

## DISCUSSION

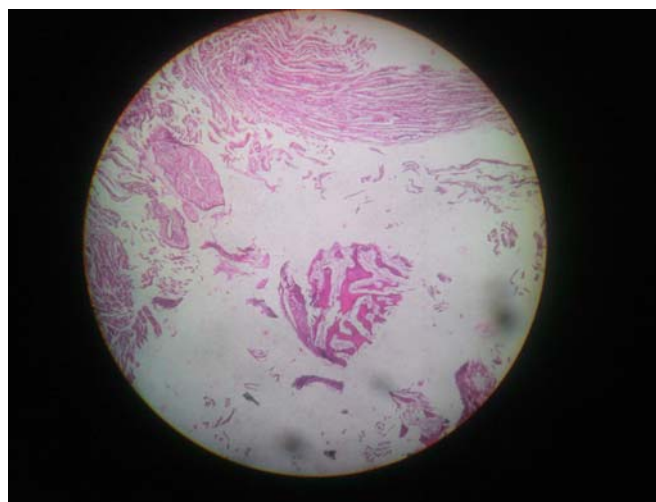Retained fetal bone in the uterine cavity post abortion is a rare cause of secondary infertility. Its incidence is unknown but they may cause significant and prolonged infertility. A study reports 0.15% incidence among 2000 diagnostic hysteroscopies<sup>1</sup>. Many cases are reported in



**Figure 1: Four pieces of bony fragments recovered from the uterine cavity**



**Figure 2: Image shows cartilage (top right), the immature bony component with bone marrow on the left of cartilage across the width of slide. On lower aspect, muscle tissue (Myometrium) is seen**



**Figure 3: Bony trabeculae surrounded by myometrium are seen in the centre of the slide**

medical literature where retained fetal bones was the cause of prolonged secondary infertility<sup>2-7</sup>. Symptoms due to this rare condition other than infertility include bleeding per vagina, dysmenorrhoea, dyspareunia and chronic pelvic pain<sup>2-7</sup>.

Retention of fetal bones usually occurs after an abortion, which maybe induced, spontaneous or missed<sup>2-7</sup>. Most authors report the retention of fetal bones after mid-trimester or late first trimester abortions<sup>2-7</sup>. The primary centres of long bones appear by 8<sup>th</sup> week of intrauterine life and develop during the second trimester<sup>8</sup>. Therefore, retention of such well-formed bones is likely to occur at this stage. The fetal bones can be freely retained in the uterine cavity or they can be embedded in the myometrium<sup>9</sup>.

There are various reasons for occurrence of secondary infertility in retained fetal bones. Many authors state that the bones act as Intra-Uterine Device by producing an increase in endometrial prostaglandins like F2 alpha and prevents blastocyst implantation<sup>2,3,7,9</sup>. Also, the retained fragments can act as foci of infection, which can spread to the tubes and derange the reproductive apparatus<sup>3</sup>. This condition may remain undetected for many years and cause long periods of distressing inability to conceive even after treatment<sup>1-7,9</sup>. Unless a clinician is aware of this condition during infertility workup, it can be easily missed on routine ultrasound imaging<sup>2-7</sup>. However, once

diagnosed and treated by removing the bones from the uterine cavity, the infertility is reverted in most cases<sup>2-7,9</sup>.

The socio-psychological impact caused by infertility is immense. It not only causes distress, depression and disappointment to the couple, but also in certain cultures and religions socially stigmatises them. In this case, the undiagnosed retained fetal bones were the cause of such long-standing infertility and was behind all the trauma faced by the deceased.

### CONCLUSION

This case highlights the importance of retained fetal bones as a significant cause of infertility after previous abortion. A high degree of suspicion and awareness of this treatable condition is required during infertility workup by the gynaecologists.

### REFERENCES

1. Makris N, Stefanidis K, Loutradis D, Anastasiadou K, Hatjipappas G, Antsaklis A. The incidence of retained foetal bone revealed in 2000 diagnostic hysteroscopies. *J Soc Laparoendoscopic Surg* 2006; 10: 76-77.
2. Moon HS, Park YH, Kwon HY, Hong SH, Kim SK. Iatrogenic secondary infertility caused by residual intrauterine fetal bone after mid trimester abortion. *Am J Obstet Gynecol* 1997; 176: 369-70.
3. Panama S, Triolo O, Arezio P. Prolonged retention of fetal bones: intrauterine device and extrauterine disease. *Clin Exp Obstet Gynecol* 1990; 17: 47-49.
4. Wokoma TT, Adum VL, Gbolade BA. Retained fetal bones masquerading as an intrauterine device with missing threads. *Eur J Contracept Reprod Health Care* 2010; 15: 213-15.
5. Usha Kiran TS, Bhal PS. The potential consequence of early recognition and treatment of retained fetal bony fragments. *Obstet Gynaecol* 2002; 22: 443-44.
6. Goldberg JM, Roberts S. Restoration of fertility after hysteroscopic removal of intrauterine bone fragments. *Obstet Gynecol* 2008; 112: 470-72.
7. Srofenyoh EK, Addison M, Dorte B, Kuffour PA. Intrauterine retained fetal bones as a cause of secondary infertility. *Ghana Med J* 2006; 40: 105-09.
8. Reddy KSN. *The Essentials of Forensic Medicine and Toxicology*. 26<sup>th</sup> edn. K. Suguna Devi, 2007.
9. Chowhan AK, Rukmangadha N, Sreedhar Babu KV, Patnayak R, Phaneendra BV, Varalakshmi Devi M *et al*. Retained intrauterine foetal bones: A rare cause of secondary infertility leading to diagnostic dilemma. *J Clin Sci Res* 2012; 1: 103-05.