

Original Article

An Autopsy Based Correlation Study about Determination of Sex from the Combined Length of Sternum (Manubrium + Body) in the Central India Indore Region (M.P.)

Pankaj Nema¹, Priyanka K. Nema^{2*}, S.K. Dadu³, B.K. Singh⁴ and P.S. Thakur⁵

¹Assistant Professor, Department of Forensic Medicine & Toxicology, ²Senior Resident, Department of Ophthalmology, Index Medical College, Indore, Madhya Pradesh, India

³Professor & Head, ⁴Associate Professor, ⁵Professor, Department of Forensic Medicine & Toxicology MGM, Medical College, Indore, Madhya Pradesh, India

(*Corresponding author) email id: *k22priya@gmail.com, ¹n12pankaj@gmail.com

Received: 24-2-2018; Accepted: 29-5-2018

ABSTRACT

Accurate determination of Sex from skeleton has been a critical issue in medico legal cases and the accuracy depends on the type of material available and methods applied. Bony remains and decomposed bodies are very important in forensic investigation. Sternum bone is very important bone for age and sex determination in the advance stage of decomposition and from mutilated, fragmented bodies Sternum is a bone which is easily retrievable even from the advance decomposed body and also from the bundle of bone. In our study Total 632 subject for sex having 350 male and 282 female of age >25 years was taken data analysis was done by using SPSS software and relevant statistical test was applied. In our study bisexual variation in relation to length of manubrium was found conclusive.

Keywords: Anthropometry, Bisexual variation, Sex determination, Combined length (M+B) length

INTRODUCTION

The cranial and pelvic bones, in addition to the long bones, are important in identifying the sex of an individual, about 98% accuracy determine from both the bone However, loss of complete bones or bones getting destroyed renders it impossible to use them for such estimations. A number of bones have been used for identification of sex including skull, pelvis, femur, etc. However, since such sex-specific bones are hard to find at each and every scene, forensic experts are left with no choice but

to depend on less sexually dimorphic elements of the human skeleton such as the sternum. Thus, studies focusing on sternum have provided important information to forensic experts ^[1]. Sternum is a bone which is easily retrievable even from the advance decomposed body and also from the bundle of bone so it become very important bone for sex determination in the advance stage of decomposition and from mutilated, fragmented bodies.

Identification of an individual is very important in criminal cases i.e. disputed paternity, assault, murder, rape, etc.

How to cite this article: Pankaj Nema, Priyanka K Nema, S.K. Dadu, B.K. Singh and P.S. Thakur. An Autopsy Based Correlation Study about Determination of Sex from the Combined Length of Sternum (Manubrium + Body) in the Central India Indore Region (M.P.). Indian Internet Journal of Forensic Medicine & Toxicology 2018; 16(2): 44-49.

and in civil cases like marriage inheritance, disputed sex etc. “Article 6 of the Universal Declaration of Human Rights” states that everyone has the right to recognition everywhere as a person before the law [2].

The main part of corpus delicti (i.e. the body of the offence; the essence of crime) is the establishment of the identity of the dead body [3,4,5].

This study is done in various region of India but is not done in central India (M.P.) region. It is establish fact that study of anthropometry result, standards differs according to different races, and different region, and it is advised that one should not used the study data of one place to other. Another purpose of study to derived a formula for this central Indian population in medico legal cases.

MATERIAL AND METHODS

This is an observational Cross sectional based analytical study done in mortuary of Department of Forensic Medicine and Toxicology M.G.M. Medical College Indore (M.P.). Study was carried out over a period of 12 month from July 2016 to June 2017. In our study Total 632 subject for sex having 350 male and 282 female of age >25 years was taken data analysis was done by using SPSS software and relevant statistical test was applied. In our study bisexual variation in relation to combined length of sternum (manubrium + body) was found conclusive.

Sternum showing any pathology, fracture, gross deformity or any missing part and body with unknown age will be excluded from the study.

As routine protocol for opening the thoracic cavity during autopsy, the sternum was removed from the body by sectioning the costal cartilages just beside the costochondral junction. For estimation of sex the elements of each sternum i.e. length of manubrium sterni was examined.

OBSERVATION AND RESULT

Table 1 shows the comparison of mean combined length of manubrium + mesosternum in relation to gender. In

Table 1: Comparison of mean combined length of manubrium + mesosternum in relation to gender

Gender	No.	Mean ± SD	‘t’ value	P value
Female	142	123.86 ± 9.52	-18.05, df=466	0.000*
Male	326	143.5 ± 11.3		

Unpaired ‘t’ test applied. P value = 0.000, Significant

the female the mean combined length of manubrium + mesosternum was 123.86 ± 9.52, while in the male it was 143.5 ± 11.3. The difference was found to be statistically significant (P<0.05), showing a longer combined length of manubrium + mesosternum in the males in comparison to the females (Figure 1).

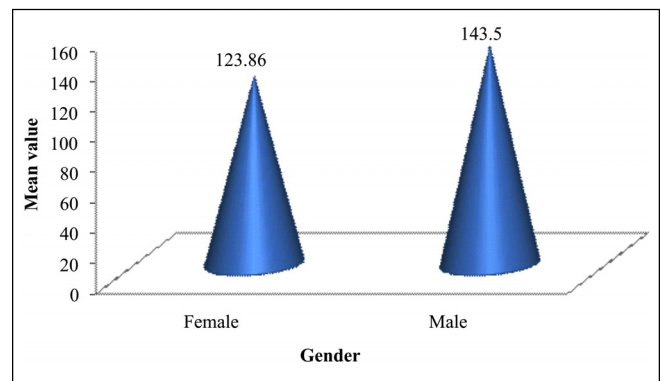


Figure 1: Cone diagram showing comparison of length of manubrium + mesosternum in relation to gender

Table 2 shows the regression analysis of gender versus combined length of manubrium (M) + mesosternum (B) in mm. The combined length of manubrium + mesosternum was found to be statistically significant (P<0.05), showing that combined length of manubrium + mesosternum will have meaningful addition to the model as changes in the predictor’s value are related to changes in the response variable. Thus, combined length of

Table 2: Regression analysis: Gender versus combined length of manubrium (M) + mesosternum (B)

	Coefficient	‘t’ value	P value
Constant	-1.624	-11.85	0.000*
Combined length of manubrium (M) + mesosternum (B)	0.023	23.33	0.000*

Regression analysis done. F value = 544.23, P value = 0.000*

manubrium + mesosternum having importance for this model. The regression equation obtained was:

$$\text{Gender} = -1.624 + 0.02361 \text{ Combined length [M+B] in mm}$$

If the equation value nears 1, then the gender is female and if the equation value nears 2, the gender is male.

Table 3 shows the discriminant analysis in finding out the gender based on the combined length of the manubrium (M) + mesosternum (B). By this method we were able to correctly identify 282 females and 350 males. The proportion of correct identification was 84.0% in females and 82.3% in males. The overall accuracy of this method was 83.1%.

Table 3: Discriminant analysis of gender based on the combined length of manubrium (M) + mesosternum (B) in mm

Combined length of manubrium (M) + Mesosternum (B)	True Group	
	Female	Male
Female	237	62
Male	45	288
Total	282	350
N correct	237	288
Proportion	84.0%	82.3%
Overall proportion correct	83.1%	

Discriminant analysis used.

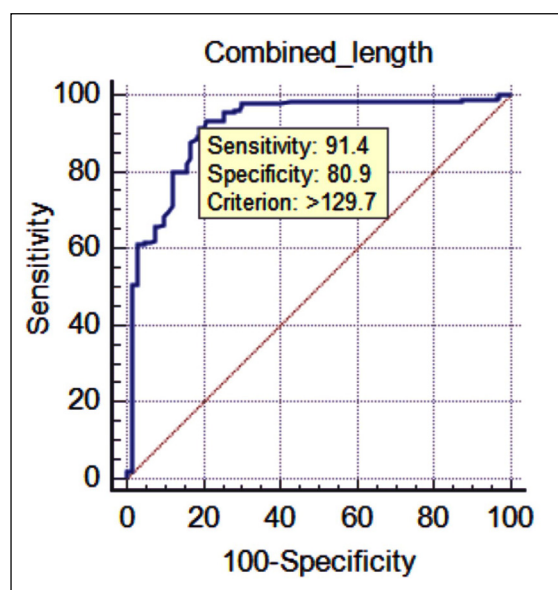


Table 4: ROC Curve [Combined length of Manubrium (M) + Mesosternum (B)]

Variable	Combined_length
Classification variable	SEX_1
Sample size	632
Positive group ^a	350(55.38%)
Negative group ^b	282(44.62%)
^a SEX_1 = Male	
^b SEX_1 = Female	
Disease prevalence (%)	unknown
Area under the ROC curve (AUC)	
Area under the ROC curve (AUC)	0.917
Standard Error ^a	0.0119
95% Confidence interval ^b	0.892 to 0.937
z statistic	35.043
Significance level P (Area=0.5)	<0.0001
^a DeLong <i>et al.</i> , 1988	
^b Binomial exact	
Youden index	
Youden index J	0.7228
Associated criterion	>129.7
Sensitivity	91.43
Specificity	80.85

The above is the ROC curve for the combined length of manubrium + mesosternum. The combined length of manubrium + mesosternum is able to correctly identify the gender in 91.43% (Sensitivity) while it was able to correctly negate the gender in 80.85% (specificity). This variable is having a good sensitivity and specificity, also according to the ROC curve, this variable is a very strong predictor of the gender (as the curve is quite near to the left hand border and left top border).

The cut-off value of Combined length of Manubrium (M) + Mesosternum (B)] is 129.7, i.e. if the Combined length of Manubrium (M) + Mesosternum (B)] is >129.7, then it is a male, else it is a female.

DISCUSSION

The observations of various workers regarding the sexual dimorphism in combined length are presented in the Table 5.

Table 5: Showing comparison of length of sternum (Mean, Regression value, difference in mean) done by various workers

Name of worker	Specimen		Combined length (M+B) in mm		
	Sex	No.	Mean	Regression equation value	Difference
Dwight (1881)	M	30		
	F	26		
Dwight (1890)	M	142	164.10	2.25	22.80
	F	86	141.30	1.71	
Paterson (1904)	M	310		
	F	126		
Ashley (1956) African	M	85	142.60	1.74	15.50
	F	13	127.10	1.37	
Ashley (1956) European	M	378	156.90	2.08	18.20
	F	168	138.70	1.65	
Jit <i>et al.</i> (1980), North India	M	312	147.08	1.84	20.06
	F	88	127.02	1.37	
Mahajan <i>et al.</i> (2009)	M	98	173.05	2.46	32.23
	F	55	140.82	1.70	
Gautam <i>et al.</i> (2003), Ahamadabad	M	56	149.00	1.89	25
	F	44	124.00	1.30	
Dahipale <i>et al.</i> (2002), Maharastra	M	96	142.20	1.73	29.32
	F	47	113.87	1.06	
Puttabanthi <i>et al.</i> (2012), Andra Pradesh	M	57	139.55	1.67	28.91
	F	22	110.64	0.98	
Adhvaryu Ankit <i>et al.</i> (2013), Saurashtra Region	M	45	141.06	1.70	18.75
	F	55	122.31	1.26	
Present Study (2017)	M	350	143.5	1.76	19.64
	F	282	123.86	1.30	

Combined length of manubrium and mesosternum (M+B)

In the present study, mean combined length of manubrium and mesosternum in male and female sterna is 143.5 mm and 123.86 mm respectively, in accordance to the observations of other Indian workers, Adhvaryu Ankit *et al.*^[12], Jit *et al.*^[13], Dahipale *et al.*^[13] and Gautam *et al.*^[4].

The difference in mean combined length (manubrium and mesosternum) of male and female sterna is 19.64 mm which is statistically highly significant ($P<0.05$) and in accordance with the value of Adhvaryu Ankit *et al.*^[12],

Ashley^[16] and Jit *et al.*^[13]. Puttabanthi *et al.*^[15] found combined length as the best discriminator of sex. They had 100% accuracy to sex female and 68.42% to sex male but in the present study accuracy to sex male is 82.3% and for female is 84.0%.

Mean value of combined length (manubrium + mesosternum) of different observer of male having more than present study is Dwight^[18], Ashley European^[16], Jit^[13], Mahajan *et al.*^[20], Gautam *et al.*^[4] and Female having more value is Dwight^[9], Ashley^[16], Jit *et al.*^[13], Mahajan *et al.*^[20].

Mean value of combined length of different observer of male having less than present study is Ashley^[16], African, Dahipale *et al.*^[14], Adhvaryu Ankit *et al.*^[12] but in female is Dahipale *et al.*^[14], Adhvaryu Ankit *et al.*^[12], Puttabanthi *et al.*^[15].

Regression analysis of present study of combined length of manubrium and mesosternum is 1.76 and 1.30 male and female respectively, which shows that if value is more than 1.5 (near 02) it is male and if less than 1.5 (near 01), on applying regression formula of present study on mean length of manubrium of different observer shows Ashley^[13], African, Jit *et al.*^[13], Gautam *et al.*^[4], Dahipale *et al.*^[14], Puttabanthi *et al.*^[15], Adhvaryu Ankit *et al.*^[12] consistent with present study.

“In the present study of all the three parameters, the mesosternum length is the most reliable parameter for determination of sex with the overall accuracy 84.0% p value less than 0.05”.

CONCLUSION

The mean combined length of manubrium + mesosternum in relation to gender which concluded that in the female the mean combined length of manubrium + mesosternum was 123.86 ± 9.52 mm, while in the male it was 143.5 ± 11.3 mm. The difference was found to be statistically significant ($P < 0.05$), showing a longer combined length of manubrium + mesosternum in the males in comparison to the females. The discriminant analysis in finding out the gender based on the combine length of the manubrium (M) + mesosternum (B) shows correct identification was 84.0% in females and 82.3% in males hence, overall accuracy 83.1%. and its regression analysis chart was found to be statistically significant ($P < 0.05$) and hence concluded by regression equation that if the equation value nears 1, then the gender is female and if the equation value nears 2, the gender is male while its ROC curve correctly identify the gender in 91.43% (Sensitivity) while it was able to correctly negate the gender in 80.85% (specificity) and resulted that The cut-off value of combine length of manubrium (M) + mesosternum (B) is 129.7 mm, i.e. if the combine length of manubrium (M) + mesosternum (B) is > 129.7 , then it is a male, else it is a female.

REFERENCES

- [1] Bongiovanni R, Spradley MK. Estimating sex of the human skeleton based on metrics of the sternum. *Forensic Science Int* 2012;219:2901-2907.
- [2] The Universal Declaration of Human rights United Nations. Available from: <http://www.un.org/en/universal-declaration-human-rights/index.html>. Accessed on 10-August, 2016.
- [3] Kaneriya D, Umarvanshi B, Patil D, Mehta C, Chauhan K, Vora R. Age determination from fusion of the sternal elements. *Int J Appl Basic Med Res* 2013;3:22-29.
- [4] Gautam R, Jadhav G, Gohil B. The human sternum – as an index of age & sex. *J Anat Soc India* 2003;52(1):20-3.
- [5] Jit I, Bakshi V. Time of fusion of the human mesosternum with manubrium & xiphoid process. *The Indian Journal of Medical Research* 1986;83:32231.
- [6] Singh J, Pathak RK, Singh D. Morphometric sex determination from various sternal widths of Northwest Indian sternums collected from autopsy cadavers: a comparison of sexing methods. *Egyptian Journal of Forensic Sciences* 2012;2(1):18-28.
- [7] Wadhawan M, Murari A, Murali G *et al.* Estimation of age from the fusion of mesosternum with manubrium and xiphisternum in Delhi: A comparative study *J Indian Acad Forensic Med* 2009;31(2):103-106.
- [8] Sobhan K. Das, is ossification of sternum at all a valuable guide for determination of age at middle age group? *JIAFM* 2005;27(1):ISSN 0971-0973
- [9] Bardale R. *Principle of forensic medicine and toxicology*, 1st edition. Jaypee Brothers Medical Publishers 2011 pp.103
- [10] Waghmare, Rupali B. Gaikwad, Vaibhav Sonar. Determination of the age with the help of ossification of the sternum. *Int J Pharm Biomed Res* 2012;3(1):5-6.
- [11] Chandrakanth HV, Kanchan T, Krishan K, Arun M, Pramod Kumar GN. Estimation of age from human sternum : An autopsy study on a sample from south India. *Int J Legal Medicine* 2012;126(6):8638.
- [12] Adhvaryu AV, Adhvaryu MA, Rathod SP, Chauhan PR, Joshi HG. A study of sexual dimorphism in human sterna. *International Journal of Medical Research & Health Sciences* 2013;2(3):577-581.
- [13] Jitindar I, Jhingan V, Kulkarni M. Sexing the human sternum. *American Journal of Physical Anthropology* 1980;53:217-224.

- [14] Dahiphale VP, Baheete BH, Kamkhedkar SG. Sexing the human sternum in Marathwada Region. *J Anat Soc India* 2002;51(2):162-167.
- [15] Puttabanthi S, Velichety D, Padi D, Boddeti D, Priyanka J. Sexing of unknown adult human sterna by metrical analysis. *Int J Biol Med Res* 2012;3(2):1516-1519.
- [16] Ashley G. A comparison of human and anthropoid mesosterna. *Am J Phys Anthropol* 1956;14(3):449-465.
- [17] Dwight T. The sternum as an index of sex and age. *Journal of Anatomy and Physiology* 1881;15(3):327.
- [18] Dwight T. The sternum is an index of sex, height and age. *Journal of Anatomy* 1890;24:527-35.
- [19] Paterson A. *The human sternum*. London: University Press of Liverpool; 1904.
- [20] Mahajan A, Batra APS, Khurana BS, Sharma SR. Sex determination of human sterna in north Indians. *Journal of Punjab Academy of Forensic Medicine and Toxicology* 2009;9(1):12-15.