

**Original Article**

## **Gross and Radiological Study of Fusion of Greater and Lesser Cornua of Hyoid Bone for Determination of Age**

**Avinash Kumar<sup>1\*</sup>, Vincent Merry<sup>2</sup>, Luv Sharma<sup>3</sup>, Jyotsna Sen<sup>4</sup> and Binay Kumar<sup>5</sup>**

<sup>1</sup>Senior Resident, Department of Forensic Medicine and Toxicology, All India Institute of Medical Sciences (AIIMS), Patna, Bihar, India

<sup>2</sup>Junior Resident (Academic), Department of Forensic Medicine, Pt. B. D. Sharma Post Graduate Institute of Medical Sciences, Rohtak, Haryana, India

<sup>3</sup>Professor, Department of Forensic Medicine, Pt. B.D. Sharma Post Graduate Institute of Medical Sciences, Rohtak, Haryana, India

<sup>4</sup>Professor, Department of Radio-diagnosis, Pt. B.D. Sharma Post Graduate Institute of Medical Sciences, Rohtak, Haryana, India

<sup>5</sup>Associate Professor, Department of Forensic Medicine and Toxicology, All India Institute of Medical Sciences (AIIMS), Patna, Bihar, India

\*Corresponding author email id: staravinash008@gmail.com

Received: 16-09-2019; Accepted: 27-09-2019

### **ABSTRACT**

The greater and lesser cornua of the hyoid bone fuse with the body at a certain age. The fusion of hyoid bone can be helpful in estimating the age of unknown dead bodies. Several investigations have shown considerable variations in the age of fusion of hyoid bone. This study was aimed at examining the age of fusion of hyoid bone in population of Haryana. Also it was designed to assess whether fusion of hyoid is sex dependent. The sample comprised hundred (equal number of male and female) healthy hyoids bones. The hyoid bones were obtained from subjects, aged between 20-70 year, in consecutive autopsies. The X-ray films were examined for the presence of fusion between the greater and lesser cornua with the body. The statistical analysis of the data was done using SPSS program for windows. The significance of the data was verified using Chi-square test, Student's t-test and ANOVA. The significance was predetermined at  $p < 0.05$ . The mean age of unilateral fusion of greater cornua in females and males were 42.67 and 45.20 years respectively while mean age of bilateral fusion were 57.40 and 59.77 years in females and males respectively. The mean age of unilateral fusion of lesser cornu in females and males were 58.00 years and 59.00 years respectively while mean age of bilateral fusion were 63.67 years and 64.23 years in females and males respectively. It was seen from the present study that the mean age of fusion did not significantly differ in the two sexes. Fractures of hyoid when found in subjects below 45 years should be evaluated more carefully. Attempt to estimate age from hyoid fusion in Indians would be unreliable owing to the regional variations.

**Keywords:** Age estimation, Bilateral, Cornua, Fusion, Hyoid bone, Unilateral

### **INTRODUCTION**

Ossification of bones provides a very useful method of estimation of age in the living. Most bones develop either from cartilage or from fibro-membranous structures.

Different bones begin and complete their ossification at different but almost fixed periods of life. These changes can be studied by X-rays and thus provide the medico-legal specialist with a very strong tool <sup>[1]</sup>.

The greater cornu and body of hyoid; and the lesser cornu and junction of body with greater cornu fuse at a certain age. The fusion of hyoid bone can be of considerable help in estimating the age of unknown dead bodies. Also in mechanical asphyxia where there is compression of the neck, fracture of hyoid bone is more likely if it is fused. So time of fusion of hyoid along with its morphology and morphometry is of considerable interest for Forensic Pathologists [2,3,4]. Several investigations have shown hyoid bone. The age at which the greater cornu fuses with the body are seen to be dependent on the population studied and the methods employed [5]. Some authors have reported that the fusion of hyoid bone occurs only after 40 years of age while other observed that the bone fused at an earlier age. Fusion was not seen in ages below 20 years while non fusion has been found even after the age of 60 years. Hence, the present study was planned to analyze the fusion of hyoid bone in different age-groups for determination of age.

Owing to variations in climatic, dietetic, hereditary and other factors affecting the people of the different states of India, it cannot be reasonably expected to formulate a uniform standard for determination of the age of fusion of hyoid bone for whole of India [6].

The times of fusion of the hyoid bone are only approximate because there are regional as well as individual variations, but even so they carry value in assessment of age. The present study, therefore, is aimed to assess the status of fusion of hyoid bone in Haryana region so that the same can be used for estimation of age of individuals in this area.

## **MATERIAL AND METHODS**

The present study was conducted in the Departments of Forensic Medicine and Radio-diagnosis, Pt. B. D. Sharma Post Graduate Institute of Medical Sciences (PGIMS), Rohtak. A total of 100 hyoid bones of known age and sex (50 males and 50 females) were collected from identified dead bodies that were brought to the Department of Forensic Medicine for post-mortem examination. The information of each case was recorded on a Proforma that included PMR number, sex, age, date of birth and gross & radiological findings. Informed

consent was obtained from the nearest of kin accompanying the dead body to the mortuary on a standard Consent Form. The study was conducted on individuals aged between 20-70 years, and for analysis, the cases were divided into 10 groups of five years interval.

### **Inclusion criteria:-**

1. Hyoid bones of normal, healthy individuals aged between 20-70 years.
2. Individuals whose exact age was known and verified (duly verified from the Birth Certificates// Matriculation Certificate/AADHAAR Card/Elector's Identity Card/Driving License).

### **Exclusion criteria:-**

1. Individuals with any congenital anomalies, partially destroyed, fractured, burnt, diseased, deformed or abnormal hyoid bones.
2. Individuals whose exact age was not known.

The hyoid bone was removed from the cadaver during post-mortem examination by careful dissection of the laryngeal structures. It was removed with extreme caution so as the bone does not break and be confused with fracture of hyoid bone. The hyoid bones thus collected were examined by palpation to examine the status of fusion of the greater cornu with the body. They were then put in labeled plastic jars containing plain tap water. After 2-3 weeks, the bones were taken out of the jars and placed in labeled plastic pouches and taken to the Radiology Department for X-ray examination. Each specimen was radiographed using Siemens Heliophos D 500 mA X-ray machine, with its inferior surface resting directly on the cassette, 100 cm from the X-ray source with an exposure of 42 kVp and 5 mAs. The cassettes were processed with digital AGFA CR System. Superior view of the bone was X-rayed to study fusion between greater cornu and body of hyoid. To study the fusion between lesser cornu and junction of body with greater cornu, antero-posterior view was taken.

The films were examined for the presence of fusion between the greater cornu and body of hyoid and

between the lesser cornu and junction of body with greater cornu. Thereafter the hyoids were classified into the following groups:

1. Those showing no fusion (UF)
2. Those showing partial fusion i.e. in the process of fusion (P)
3. Those showing complete fusion (F)-
  - (i) Unilateral Left
  - (ii) Unilateral Right
  - (iii) Bilateral

The statistical analysis of the data was done using SPSS program for windows. The significance of the data was verified using Chi-square test, Student's t-test and ANOVA. The significance was predetermined at  $p < 0.05$ . Photographs in Image 1 and 2.

## OBSERVATIONS AND RESULTS

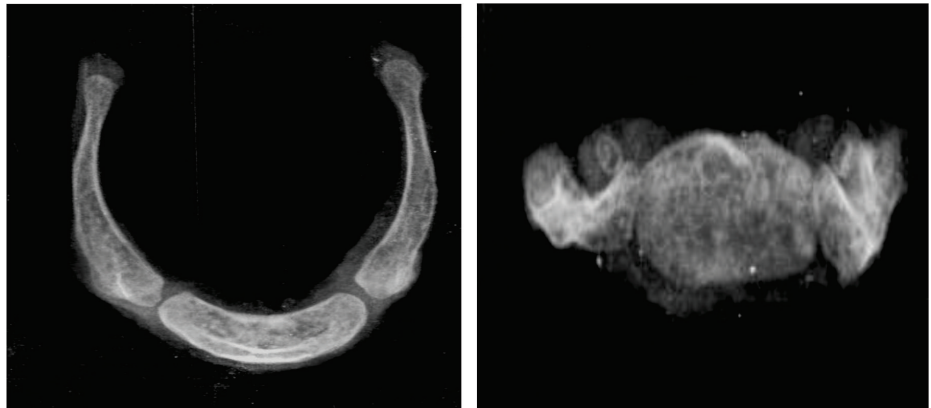
The X-ray films were examined and observations regarding the status of fusion between the greater cornu and body of hyoid were noted.

Table 1 depicts the age and sex wise distribution of the hyoid bones taken for the study. In females, the maximum and minimum number of samples were in the age groups 65-70 years ( $n=7$ ) and 61-65 years ( $n=3$ ) respectively while in males it was in the age groups 21-25 yrs & 61-65 years ( $n=7$ ) and 26-30 yrs & 65-70 years respectively.

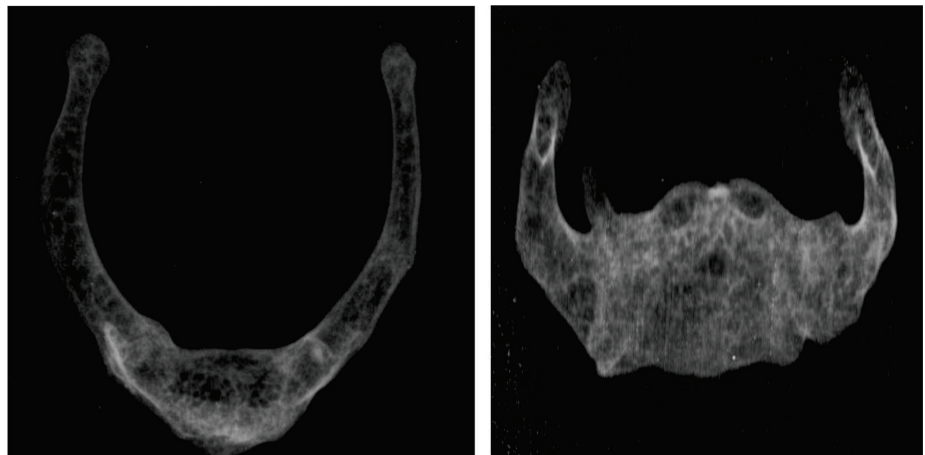
From the Table 2 and Graph 1 it is observed that in females, there was no fusion of greater cornua with the body in the age groups 20-25 and 26-30 years.

The earliest in-process of fusion was seen in the age group 31-35 years (in 1 out of 5 cases i.e. 20%) whereas earliest unilateral fusion and bilateral in-process of fusion

**Image 1: Showing Non-fusion of Greater and Lesser Horns in a 29 year old Female**



**Image 2: Showing Bilateral Fusion of Greater Cornua and Lesser Cornua in a 65 year old Male**



**Table 1: Age and Sex-Wise Distribution of Subjects**

Age Groups (years)	Female (n=50)		Male (n=50)		Total (n=100)	
	(n)	(%)	(n)	(%)	(n)	(%)
21–25 years	6	46.2	7	53.8	13	100
26–30 years	4	57.1	3	42.9	7	100
31–35 years	5	55.6	4	44.4	9	100
36–40 years	5	45.5	6	54.5	11	100
41–45 years	6	60.0	4	40.0	10	100
46–50 years	4	40.0	6	60.0	10	100
51–55 years	4	50.0	4	50.0	8	100
56–60 years	6	50.0	6	50.0	12	100
61–65 years	3	30.0	7	70.0	10	100
Above 65 years	7	70.0	3	30.0	10	100
Total	50	50.0	50	50.0	100	100

**Table 2: Status of Fusion of Greater Cornua among Females**

Age group (years)	Bilateral Un-fused (UF)		Unilateral Fused (F)		Bilateral Fused (F)		Unilateral In-process (P)		Bilateral In-process (P)		Total (T)	
	(n)	(%)	(n)	(%)	(n)	(%)	(n)	(%)	(n)	(%)	(n)	(%)
20–25 years	6	(100)	0	(0)	0	(0)	0	(0)	0	(0)	6	(100)
26–30 years	4	(100)	0	(0)	0	(0)	0	(0)	0	(0)	4	(100)
31–35 years	4	(80)	0	(0)	0	(0)	1	(20)	0	(0)	5	(100)
36–40 years	1	(20)	1	(20)	0	(0)	1	(20)	2	(40)	5	(100)
41–45 years	2	(33.3)	2	(33.3)	1	(16.7)	1	(16.7)	0	(0)	6	(100)
46–50 years	0	(0)	2	(50)	2	(50)	0	(0)	0	(0)	4	(100)
51–55 years	0	(0)	0	(0)	4	(100)	0	(0)	0	(0)	4	(100)
56–60 years	1	(16.7)	0	(0)	5	(83.3)	0	(0)	0	(0)	6	(100)
61–65 years	0	(0)	0	(0)	3	(100)	0	(0)	0	(0)	3	(100)
Above 65 years	0	(0)	0	(0)	7	(100)	0	(0)	0	(0)	7	(100)
Total	18	(36)	5	(10)	22	(44)	3	(6)	2	(4)	50	(100)

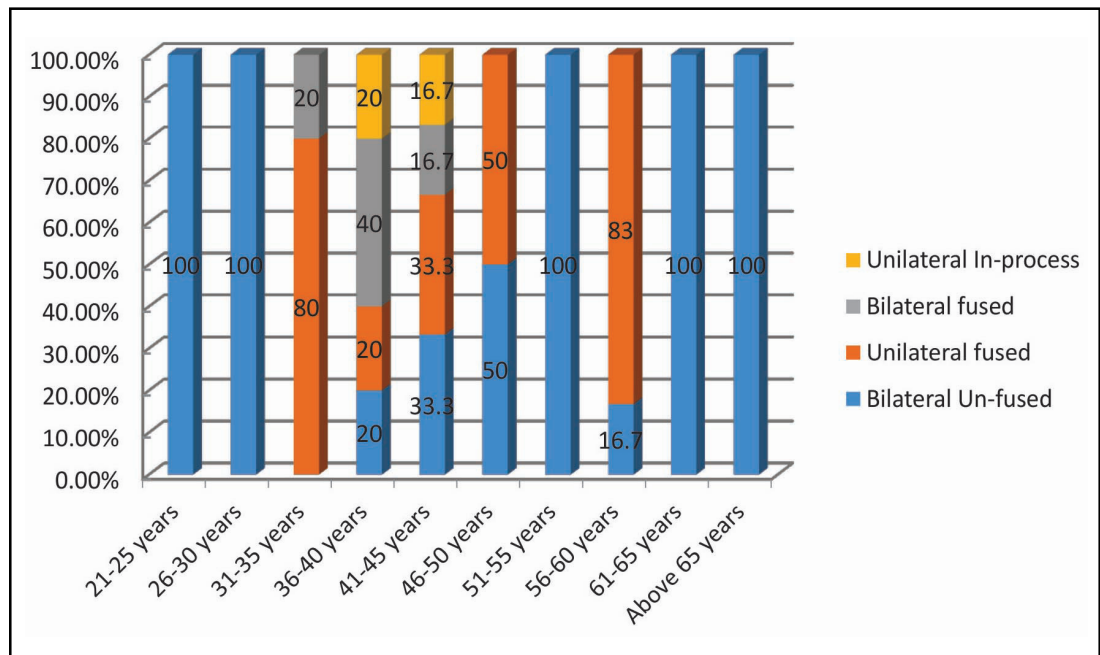
were seen in the age group 36-40 years (in 1 out of 5 cases each, i.e. 20% each). Earliest complete bilateral fusion was observed in age group 41-45 years (in 1 out of 6 cases i.e. 16.7%). Bilateral non-fusion was observed even in age group 56-60 years.

From the Table 3 and Graph 2 it is observed that in males, there was no fusion of greater cornua with the body in the first three age groups.

The earliest unilateral In-process of fusion was seen in the age group 36-40 years (in 2 out of 6 cases i.e. 33.3%). Earliest complete bilateral fusion was also seen in the age group 36-40 years (in 2 out of 6 cases i.e. 33.3%). Bilateral non-fusion was observed even in the age group 46-50 years (in 2 out of 6 cases i.e. 33.3%).

From the Table 4 and Graph 3 it is observed that in males, out of the total 50 cases, non-fusion between the body

**Graph 1: Distribution of fusion of Greater Cornua in Females**



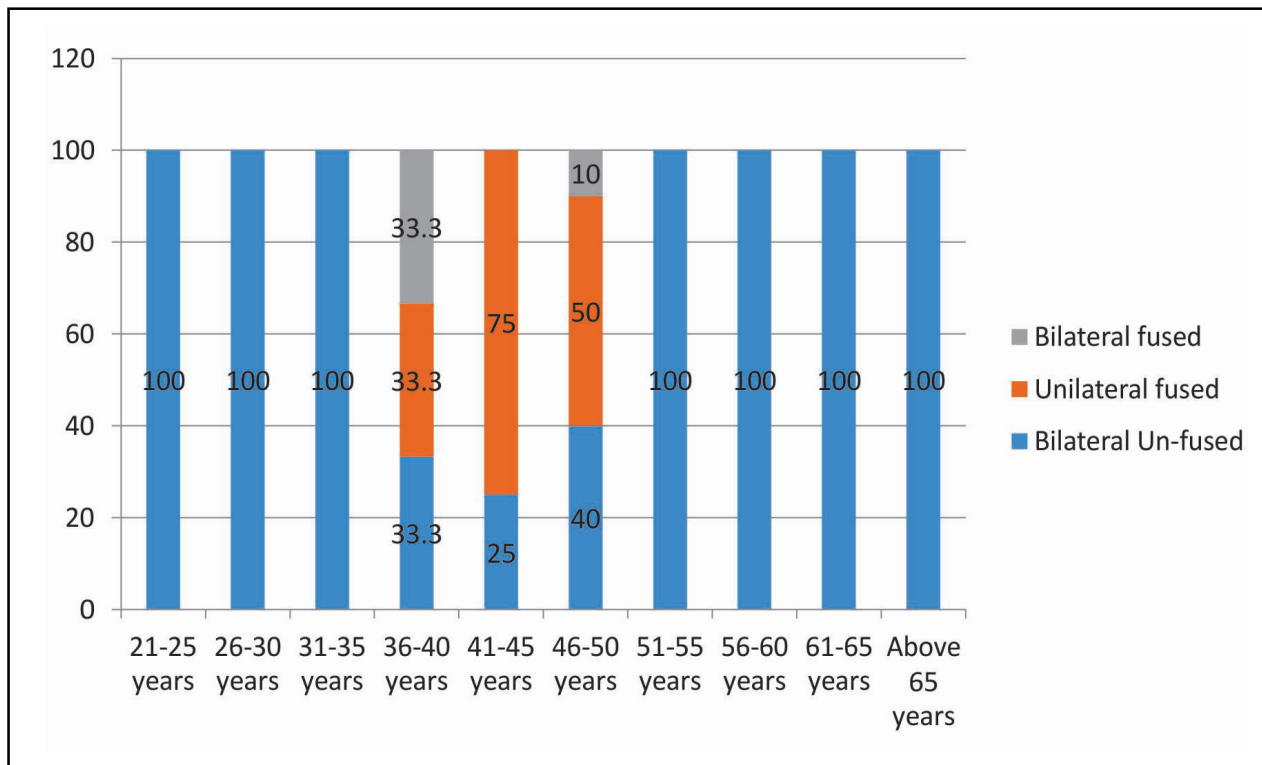
**Table 3: Status of Fusion of Greater Cornua among Males**

Age group (years)	Bilateral Un-fused (UF)		Unilateral Fused (F)		Bilateral Fused (F)		Unilateral In-process (P)		Total (T)	
	(n)	(%)	(n)	(%)	(n)	(%)	(n)	(%)	(n)	(%)
21–25 years	7	(100)	0	(0)	0	(0)	0	(0)	7	(100)
26–30 years	3	(100)	0	(0)	0	(0)	0	(0)	3	(100)
31–35 years	4	(100)	0	(0)	0	(0)	0	(0)	4	(100)
36–40 years	2	(33.3)	0	(0)	2	(33.3)	2	(33.4)	6	(100)
41–45 years	1	(25)	3	(75)	0	(0)	0	(0)	4	(100)
46–50 years	2	(40)	0	(0)	3	(50)	1	(10)	6	(100)
51–55 years	0	(0)	0	(0)	4	(100)	0	(0)	4	(100)
56–60 years	0	(0)	0	(0)	6	(100)	0	(0)	6	(100)
61–65 years	0	(0)	0	(0)	7	(100)	0	(0)	7	(100)
Above 65 years	0	(0)	0	(0)	3	(100)	0	(0)	3	(100)
Total	19	(38)	3	(6)	25	(50)	3	(6)	50	(100)

and greater cornu was seen in 19 cases (38.0%) bilaterally while complete fusion was seen in 25 cases (50.0%) bilaterally and 3 cases (6.0%) unilaterally. Unilateral In-process of fusion was seen in 3 cases (6.0%). In females, out of the total 50 cases, non-fusion was seen in 18 cases (36.0%) bilaterally while complete fusion was seen in 22 cases (44.0%) bilaterally and 5

cases (10.0%) unilaterally. Unilateral In-process of fusion was seen in 3 cases (6.0%) and bilateral in-process in 2 cases (4.0%).

From the Table 5, the mean age of un-fused greater cornu in males and females were 33.48 years and 32.68 years respectively while mean age of fused (bilateral) greater



**Graph 2: Distribution of fusion of Greater Cornua in Males**

cornu were 59.77 years and 57.40 years respectively. The mean age of unilateral fusion in males and females were 45.20 years and 42.67 years respectively. In case of unilateral in-process of fusion, the mean age in males and females were 43.67 years and 41.50 years respectively.

No significant statistical sexual difference in the incidence of fusion of greater cornu was observed in all the age groups.

From Table 6 to 15 it is clear that no statistically significant difference was found between males and females who had bilateral non-fusion ( $p=0.800$ ), unilateral fusion ( $p=0.766$ ) and bilateral fusion ( $0.769$ ).  $p$  value is less than 0.001 and therefore there is very highly statistically significant difference between the ages of fusion of lesser cornua in the mentioned age groups.

## DISCUSSION

The present investigation was designed to examine the age at which the body of hyoid bone fuses (calcifies)

with the greater and lesser cornu in different age groups. The body of the hyoid bone fuses with the greater and lesser cornu as a process of development. This fusion takes place at variable age and is depend on several factors including sex and population, as supported by previous researches [7,8,9], especially in a multi ethnic country like India. Therefore, it is difficult to follow a single standard data for determination of age for the entire country.

In the present study, the status of fusion of the greater and lesser cornua of the hyoid bone in males and females of Haryana was studied and the results were compared with previous similar studies.

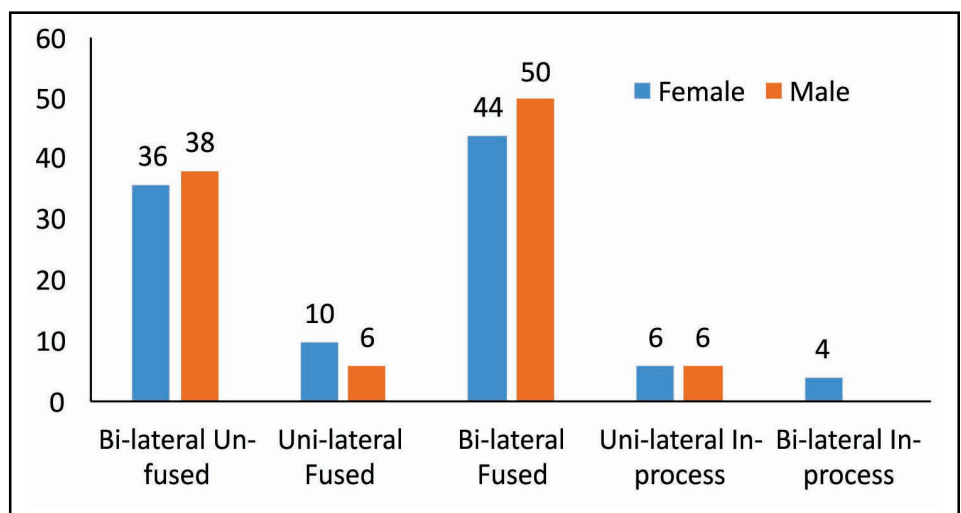
## CONCLUSION

The mean age of unilateral fusion of greater cornu in females and males were 42.67 and 45.20 respectively while mean age of bilateral fusion were 57.40 and 59.77 in females and males respectively. The mean age of unilateral fusion of lesser cornu in females and males

**Table 4: Status of Fusion of Greater Cornua among Males and Females**

Age group		Female						Male				
		Bi-lateral Un-fused (UF)	Uni-lateral Fused (F)	Bi-lateral Fused (F)	Uni-lateral In-process (P)	Bi-lateral In-process (P)	Total (T)	Bi-lateral Un-fused (UF)	Uni-lateral Fused (F)	Bi-lateral Fused (F)	Uni-lateral In-process (P)	Total (T)
21–25 Years	(n)	6	0	0	0	0	6	7	0	0	0	7
	(%)	100.0	0.0	0.0	0.0	0.0	100	100.0	0.0	0.0	0.0	100
26–30 years	(n)	4	0	0	0	0	4	3	0	0	0	3
	(%)	100.0	0.0	0.0	0.0	0.0	100	100.0	0.0	0.0	0.0	100
31–35 years	(n)	4	0	0	1	0	5	4	0	0	0	4
	(%)	80.0	0.0	0.0	20.0	0.0	100	100.0	0.0	0.0	0.0	100
36–40 years	(n)	1	1	0	1	2	5	2	0	2	2	6
	(%)	20.0	20.0	0.0	20.0	40.0	100	33.3	0.0	33.3	33.4	100
41–45 years	(n)	2	2	1	1	0	6	1	3	0	0	4
	(%)	33.3	33.3	16.7	16.7	0.0	100	25.0	75.0	0.0	0.0	100
46–50 years	(n)	0	2	2	0	0	4	2	0	3	1	6
	(%)	0.0	50.0	50.0	0.0	0.0	100	40.0	0.0	50.0	10.0	100
51–55 years	(n)	0	0	4	0	0	4	0	0	4	0	4
	(%)	0.0	0.0	100.0	0.0	0.0	100	0.0	0.0	100.0	0.0	100
56–60 years	(n)	1	0	5	0	0	6	0	0	6	0	6
	(%)	16.7	0.0	83.3	0.0	0.0	100	0.0	0.0	100.0	0.0	100
61–65 years	(n)	0	0	3	0	0	3	0	0	7	0	7
	(%)	0.0	0.0	100.0	0.0	0.0	100	0.0	0.0	100.0	0.0	100
Above 65 years	(n)	0	0	7	0	0	7	0	0	3	0	3
	(%)	0.0	0.0	100.0	0.0	0.0	100	0.0	0.0	100.0	0.0	100
Total	(n)	18	5	22	3	2	50	19	3	25	3	50
	(%)	36.0	10.0	44.0	6.0	4.0	100	38.0	6.0	50.0	6.0	100

**Graph 3: Distribution of fusion of Greater Cornua among Males and Females**



**Table 5: Mean Age of Fusion of Greater Cornua in Males & Females, Standard Deviation and Corresponding p-Values**

Greater Cornua	Female			Male			p-value
	Mean	Standard Deviation	Standard Error of Mean	Mean	Standard Deviation	Standard Error of Mean	
Bilateral Un-fused	32.68	8.65	±1.22	33.48	9.50	±1.34	0.770
Unilateral Fused	42.67	2.08	±0.29	45.20	4.55	±0.64	0.408
Bilateral Fused	57.40	8.31	±1.17	59.77	7.60	±1.07	0.315
Unilateral In-Process	41.50	0.71	±0.10	43.67	5.13	±0.72	0.045*
Bilateral In-Process	39.50	0.71	±0.10				

Unpaired t-test; \*Significant Difference; p-value < 0.05 is statistically significant

**Table 6: Mean age of Fusion of Lesser Cornua in Males and Females, Standard Deviation and corresponding p-values**

Lesser Cornua	Female			Male			p-value
	Mean	Standard Deviation	Standard Error of Mean	Mean	Standard Deviation	Standard Error of Mean	
Bilateral Un-fused	38.40	10.89	±1.54	38.80	11.16	±1.57	0.800#
Unilateral Fused	58.00	4.00	±0.56	59.00	1.41	±0.19	0.766#
Bilateral Fused	63.67	3.82	±0.54	64.23	5.46	±0.77	0.769#

Unpaired t-test; #Non-Significant Difference; p-value > 0.05 is not statistically significant

**Table 7: Comparison of Status of Fusion of Lesser Cornua according to Gender in Different Age Groups**

Lesser Cornua	Mean Age	Standard Deviation
Bilateral Un-fused	38.60	10.95
Unilateral Fused	58.40	2.97
Bilateral Fused	63.96	4.66
p-value	0.001***	

One-way ANOVA test; \*\*\* Very Highly Significant difference; p-value = 0.001 is very highly statistically significant

were 58.00 years and 59.00 years respectively while mean age of bilateral fusion were 63.67 years and 64.23 years in females and males respectively. Statistically, there was no statistically significant sexual difference (p value > 0.5) between incidence of fusion of greater and lesser cornua in all the age groups. The present study has attempted to provide a reference for age determination from the hyoid bone for a population of Haryana.

**Table 8: Comparison of Status of Unilateral Fusion of Greater Cornua with Earlier Studies**

Study	Earliest Age of Unilateral Fusion of Greater Cornua in years	
	Female	Male
<b>Indian Studies</b>		
Gupta <i>et al.</i> 2008 (Delhi) <sup>[9]</sup>	25-30	25-30
D' Souza <i>et al.</i> 2010 (South India) <sup>[10]</sup>	20	21-30
Harjeet <i>et al.</i> 2010 (North West India) <sup>[11]</sup>	26-30	26-30
<b>Foreign Studies</b>		
Parsons, 1909 (London) <sup>[12]</sup>	20	21-30
O'Halloran and Lundy, 1987 (United States) <sup>[13]</sup>	20	20-29
Balsevan-Odabasi <i>et al.</i> 2013 (Turkey) <sup>[14]</sup>	21-30	21-30
Current Study	41-45	36-40

**Table 9: Comparison of Percentage of Unilateral Fusion of Greater Cornua with Earlier Studies**

Study	Percentage of Unilateral Fusion of Greater Cornua in years (%)	
	Female	Male
<b>Indian Studies</b>		
Gupta <i>et al.</i> 2008 (Delhi) <sup>[9]</sup>	11.2	20.2
D' Souza <i>et al.</i> 2010 (South India) <sup>[10]</sup>	24.4	28.3
Harjeet <i>et al.</i> 2010 (North West India) <sup>[11]</sup>	7.5	6
<b>Foreign Studies</b>		
O'Halloran and Lundy, 1987 (United States) <sup>[13]</sup>	36	15.1
Balsevan-Odabasi <i>et al.</i> 2013 (Turkey) <sup>[14]</sup>	25	22.6
<b>Current Study</b>	<b>10</b>	<b>6</b>

**Table 10: Comparison of Status of Bilateral Fusion of Greater Cornua with Earlier Studies**

Study	Earliest Age of Bilateral Fusion of Greater Cornua in years	
	Female	Male
<b>Indian Studies</b>		
Gupta <i>et al.</i> 2008 (Delhi) <sup>[9]</sup>	30-35	35-40
D' Souza <i>et al.</i> 2010 (South India) <sup>[10]</sup>	21-30	21-30
Harjeet <i>et al.</i> 2010 (North West India) <sup>[11]</sup>	26-30	26-30
<b>Foreign Studies</b>		
Parsons, 1909 (London) <sup>[12]</sup>	31-40	31-40
O'Halloran and Lundy, 1987 (United States) <sup>[13]</sup>	20-29	20-29
Balsevan-Odabasi <i>et al.</i> 2013 (Turkey) <sup>[14]</sup>	21-30	21-30
<b>Current Study</b>	<b>41-45</b>	<b>36-40</b>

**Table 11: Comparison of Percentage of Bilateral Fusion of Greater Cornua with Earlier Studies**

Study	Percentage of Bilateral Fusion of Greater Cornua in years (%)	
	Female	Male
<b>Indian Studies</b>		
Gupta <i>et al.</i> 2008 (Delhi) <sup>[9]</sup>	35.2	30.3
D' Souza <i>et al.</i> 2010 (South India) <sup>[10]</sup>	8.1	16
Harjeet <i>et al.</i> 2010 (North West India) <sup>[11]</sup>	26.9	16.5
<b>Foreign Studies</b>		
O'Halloran and Lundy, 1987 (United States) <sup>[13]</sup>	22.7	37.3
Balsevan-Odabasi <i>et al.</i> 2013 (Turkey) <sup>[14]</sup>	56.3	66
<b>Current Study</b>	<b>44</b>	<b>50</b>

**Table 12: Comparison of Mean Age of Fusion of Greater Cornua with Earlier Studies**

Study	Mean Age of Fusion of Greater Cornua (years)			
	Female		Male	
	Unilateral	Bilateral	Unilateral	Bilateral
<b>Indian Studies</b>				
Gupta <i>et al.</i> 2008 (Delhi) <sup>[9]</sup>	38.00	48.50	38.25	53.16
D' Souza <i>et al.</i> 2010 (South India) <sup>[10]</sup>	37.50	45.00	39.39	41.77
Biswas <i>et al.</i> 2013 (West Bengal) <sup>[15]</sup>	-	55.57	-	59.0
<b>Current Study</b>	<b>42.67</b>	<b>57.40</b>	<b>45.20</b>	<b>59.77</b>

**Table 13: Frequency of Bilateral Fusion of Greater Cornua in Males and Females**

Study	Frequency of Bilateral Fusion of Greater Cornua	
	Female	Male
O'Halloran and Lundy, 1987 (United States) <sup>[13]</sup>	22.7%	37.3%
Current Study	44%	50%

**Table 14: Status of Fusion of Greater Cornua in Subjects above 60 Years**

Study	Age Group (> 60 years)					
	Female			Male		
	(n)	Total	(%)	(n)	Total	(%)
Balsevan-Odabasi <i>et al.</i> 2013 (Turkey) <sup>[14]</sup>	7	7	100	11	11	100
Gupta <i>et al.</i> 2008 (Delhi) <sup>[9]</sup>	3	3	100	7	7	100
Current Study	10	10	100	10	10	100

**Table 15: Comparison of Status of Fusion of Lesser Cornua with Earlier Studies**

Study	Female	Male
<b>Earliest Age of Unilateral Fusion of Lesser Cornua (Years)</b>		
Parsons, 1909 (London) <sup>[16]</sup>	>49	36
Harjeet <i>et al.</i> 2010 (North West India) <sup>[11]</sup>	41-50	36-40
Current Study	56-60	51-55
<b>Earliest Age of Bilateral Fusion of Lesser Cornua (Years)</b>		
Parsons, 1909 (London) <sup>[16]</sup>	>49	>49
Harjeet <i>et al.</i> 2010 (North West India) <sup>[11]</sup>	41-50	36-40
Current Study	51-55	56-60

## REFERENCES

- [1] Agrawal A. Age Estimation in the living: in matters civil and criminal. *Journal of Anatomy*. 2009; 1(2): 1–25.
- [2] Holloran RL, Lundy JK. Age and ossification of the hyoid bone: forensic implications. *Journal of Forensic Science*. 1987; 32: 1655–9.
- [3] Mukhopadhyay PP. Predictors of hyoid fracture in hanging: Discriminant function analysis of morphometric variables. *Legal Medicine*. 2010; 12(3): 113–16.
- [4] Mukhopadhyay PP. Morphometric features and sexual dimorphism of adult hyoid bone: A population specific study with forensic implications. *Journal of Forensic Legal Medicine*. 2010; 17(6): 321–24.
- [5] Shimizu Y, Kanetaka H, Kim YH, Okayama K, Kano M, Kikuchi M. Age related morphological changes in human hyoid bone. *Cells Tissues Organs*. 2005; 180:185–92.
- [6] Mathiharan K, Kannan K, Modi A. *Textbook of Medical Jurisprudence and Toxicology*. 24th ed. Nagpur: LexisNexis Butterworths Wadhwa. 2012; 238–50.
- [7] O'Holloran RL, Lundy JK. Age and ossification of the hyoid bone: forensic implications. *Journal of Forensic Science*. 1987; 32: 1655–9
- [8] Kanetaka H, Shimizu Y, Kano M, Kikuchi M. Synostosis of the joint between the body and greater cornu of the human hyoid bone. *Clinical Anatomy*. 2011; 24: 837–842.
- [9] Gupta A, Kohli A, Aggarwal NK, Banerjee KK. Study of age of fusion of hyoid bone. *Legal Medicine*. 2008; 10: 253–6.
- [10] D' Souza DH, Harish SS, Kiran J. Fusion in the hyoid

- bone: usefulness and implications. *Journal of Medicine Science and Law* 2010; 50(4): 197–9.
- [11] Harjeet K, Syngal S, Kaur G, Aggarwal A, Wahee P. Time of fusion of greater cornu with body of hyoid bone in North-West Indians. *Journal of Legal Medicine*. 2010; 12(5): 223–7.
- [12] Parsons FG. The topography and morphology of human hyoid bone. *Journal of Anatomy Physiology*. 1909; 43(4): 279–90.
- [13] O'Halloran RL, Lundy JK. Age and ossification of the hyoid bone: Forensic Implications. *Journal of Forensic Science*. 1987; 32(6): 1655–9.
- [14] Balsevan-Odabasi A, Yalcinozan E, Keten A, Akçan R, Tumer AR, Onan A *et al*. Age and sex estimation by metric measurements and fusion of hyoid bone in a Turkish population. *Journal of Forensic Legal Medicine*. 2013; 20(5): 496–501.
- [15] Biswas A, Mazumdar S, Sardar T. Fusion of Hyoid Bone: A Preliminary Study in Indian Bengali. *Journal of Indian Academic Forensic Medicine*. 2013; 35(1): 14–6.
- [16] Parsons FG. The topography and morphology of human hyoid bone. *Journal of Anatomy Physiology*. 1909; 43(4): 279–90.

**How to cite this article:** Avinash Kumar, Vincent Merry, Luv Sharma, Jyotsna Sen and Binay Kumar. Gross and Radiological Study of Fusion of Greater and Lesser Cornua of Hyoid Bone for Determination of Age. *Indian Internet Journal of Forensic Medicine & Toxicology*. 2019; 17(4): 73-83.